

Supplement to

May/June 2020

CRST MODERN OPTOMETRY

Cataract & Refractive Surgery Today

NEUROTROPHIC KERATITIS:

New Approaches
to Manage Disease
and Improve Patient
Satisfaction

Marjan Farid, MD

Terry Kim, MD

Francis S. Mah, MD

Distributed with

CRST

Cataract & Refractive Surgery Today

MODERN OPTOMETRY

Sponsored by



OFFICE OF CONTINUING PROFESSIONAL EDUCATION

Provided by


evolve
medical education



A CME/CE activity provided by Evolve Medical Education LLC.

This activity is supported by an independent, unrestricted medical education grant from Dompé.

Neurotrophic Keratitis:

New Approaches to Manage Disease and Improve Patient Satisfaction

Release Date: May 1, 2020
CME Expiration May 31, 2021
COPE Expiration Date: April 20, 2023

FACULTY



MARJAN FARID, MD

Professor of Ophthalmology, School of Medicine
Vice Chair of Ophthalmic Faculty
Director, Cornea/External Disease, Cataract and
Refractive Surgery
Gavin Herbert Eye Institute, UC Irvine
Irvine, California



TERRY KIM, MD

Professor of Ophthalmology
Duke University School of Medicine
Chief, Cornea and External Disease Division
Director, Refractive Surgery Service
Duke University Eye Center
Durham, North Carolina



FRANCIS S. MAH, MD

Director, Cornea and External Disease
Co-Director, Refractive Surgery
Scripps Clinic
La Jolla, California

CONTENT SOURCE

This continuing medical education (CME)/continuing education (CE) activity captures content from two webcasts.

ACTIVITY DESCRIPTION

Neurotrophic keratitis is a degenerative corneal disease characterized by decreased or absent corneal sensation, which can lead to epithelial breakdown, impairment of healing, and ultimately to the development of corneal ulceration, melting and perforation. Treating neurotrophic keratitis should be prompt and based on the stage and severity of the disease. However, this disease remains difficult and challenging to treat, and eye care providers need to be informed of the most recent advances in treatment.

TARGET AUDIENCE

This certified CME/CE activity is designed for specialists and other allied eye care practitioners involved in the management of neurotrophic keratitis.

LEARNING OBJECTIVES

Upon completion of this activity, the participant should be able to:

- **Describe** the stages of neurotrophic keratitis, and how to differentiate it from similar diseases
- **Recognize** the various potential causes of neurotrophic keratitis

- **Understand** mechanisms of action of newer treatments and when they should be introduced into treatment regimens for neurotrophic keratitis
- **Identify** the relationships between disease characteristics, drug, treatment frequency, visual and anatomic outcomes

GRANTOR STATEMENT

This activity is supported by an independent, unrestricted medical education grant from Dompé.

ACCREDITATION STATEMENT

Evolve Medical Education LLC (Evolve) is accredited by the Accreditation Council for Continuing Medical Education (ACCME) to provide continuing medical education for physicians.

Evolve is an approved COPE Administrator.

CREDIT DESIGNATION STATEMENT

Evolve designates this enduring material for a maximum of 1 AMA PRA Category 1 Credit™. Physicians should claim only the credit commensurate with the extent of their participation in the activity.

This course is COPE approved for 1.0 hour of CE credit for optometrists.

COPE Course ID: 67919-AS
COPE Event ID: 119360



TO OBTAIN CREDIT

To obtain credit for this activity, you must read the activity in its entirety and complete the Pretest/Posttest/Activity Evaluation/Satisfaction Measures Form, which consists of a series of multiple-choice questions. To answer these questions online and receive real-time results, please click <https://evolvemeded.com/online-courses/1935-supplement>. Upon completing the activity and self-assessment test, you may print out a CME credit letter awarding 1 AMA PRA Category 1 Credit™ or a CE Credit letter awarding 1 COPE Credit. Alternatively, please complete the Posttest/Activity Evaluation/Satisfaction Form and mail or fax to Evolve Medical Education LLC, 353 West Lancaster Avenue, Second Floor, Wayne, PA 19087; Fax: (215) 933-3950.

DISCLOSURE POLICY

It is the policy of Evolve that faculty and other individuals who are in the position to control the content of this activity disclose any real or apparent conflict of interests relating to the topics of this educational activity. Evolve has full policies in place that will identify and resolve all conflicts of interest prior to this educational activity.

The following faculty/staff members have the following financial relationships with commercial interests:

Marjan Farid, MD, and/or spouse/partner has had a financial agreement or affiliation during the past year with the following commercial interests in the form of *Consultant*: Biotissue, CorneaGen, and Novartis. *Grant/Research Support*: Allergan, Dompé, and Johnson & Johnson Vision.

Terry Kim, MD, and/or spouse/partner has had a financial agreement or affiliation during the past year with the following commercial interests in the form of *Consultant*: Aerie Pharmaceuticals, Alcon, Allergan, Avedro, Avellino

Labs, Bausch + Lomb, Blephex, CorneaGen, Dompé, Eyenovia, Johnson & Johnson Vision, Kala Pharmaceuticals, Novabay Pharmaceuticals, Novartis, Ocular Therapeutix, Omeros, Presbyopia Therapies, Shire, Sight Sciences, Simple Contacts, Surface, and Zeiss.

Francis S. Mah, MD, and/or spouse/partner has had a financial agreement or affiliation during the past year with the following commercial interests in the form of *Consultant*: Dompé.

EDITORIAL SUPPORT DISCLOSURES

Erin K. Fletcher, MIT, director of compliance and education; Susan Gallagher-Pecha, director of client services and project management; Cassandra Richards, director of education development, Evolve; and Virginia Pickles, writer, have no financial relationships with commercial interests. Nisha Mukherjee, MD, peer reviewer, have no financial relationships with commercial interests.

OFF-LABEL STATEMENT

This educational activity may contain discussion of published and/or investigational uses of agents that are not indicated by the FDA. The opinions expressed in the educational activity are those of the faculty. Please refer to the official prescribing information for each product for discussion of approved indications, contraindications, and warnings.

DISCLAIMER

The views and opinions expressed in this educational activity are those of the faculty and do not necessarily represent the views of Evolve, *Cataract & Refractive Surgery Today*, *Modern Optometry*, or Dompé.

DIGITAL EDITION

To view the online version of the material, please click <https://evolvemeded.com/online-courses/1935-supplement>.



PRETEST QUESTIONS

PLEASE COMPLETE PRIOR TO ACCESSING THE MATERIAL AND SUBMIT WITH POSTTEST/ACTIVITY EVALUATION/SATISFACTION MEASURES INSTRUCTIONS FOR CME CREDIT.

- Please rate your confidence in your ability to diagnose neurotrophic keratitis.**
 - Not at all confident
 - Not very confident
 - Neutral
 - Confident
 - Very confident
- Corneal sensitivity testing is a key step in diagnosing neurotrophic keratitis. Of the following, all are qualitative tests, NOT quantitative, EXCEPT:**
 - Cotton wisp
 - Tip of a tissue
 - Cochet-Bonnet esthesiometer
 - Unwaxed dental floss
- Which of the following are risk factors for a 75-year-old man with a previous history of "corneal abrasion"?**
 - History of Herpes zoster
 - History of nonhealing epithelial defect
 - History of LASIK
 - All of the above
- What are some therapeutic options for nonhealing epithelial defect after corneal transplant?**
 - Bandage contact lens
 - Tarsorrhaphy
 - Serum drops
 - Cenegermin-bkbj
 - All of the above
- What percent of patients remained healed 1 year (48 weeks) after cessation of treatment in the REPARO trial?**
 - 10%
 - 50%
 - 80%
 - 100%
- In clinical trials of cenegermin 20 mcg/mL on neurotrophic keratitis patients, how many of the up to 72% that healed were still healed a year later (48 weeks) without any additional therapy?**
 - 10%
 - 25%
 - 50%
 - 80%
- A 78-year-old woman with a history of diabetic neuropathy and proliferative diabetic retinopathy is referred following a pars plana vitrectomy with irregular whorling epithelium causing decreased vision. Her referring eye care specialist has tried preservative-free artificial tears hourly, escalated to gels and ointments as well as topical lifitegrast then topical cyclosporine, and recently tried a self-retaining amniotic membrane without much change in the clinical appearance. It's been a couple months and although there isn't an epithelial defect, the patient is getting frustrated at the lack of vision, but otherwise is in little discomfort. The appropriate next step should be the following:**
 - Testing for corneal sensitivity
 - Temporary lateral tarsorrhaphy
 - Placing a bandage contact lens
 - Gunderson style conjunctival flap
 - Culture to rule out infection
- Which topical treatment for neurotrophic keratitis is structurally identical to the nerve growth factor protein?**
 - Corticosteroids
 - Autologous serum eyedrops
 - Antibiotics
 - Cenegermin-bkbj
- In the United States, NK affects how many people?**
 - Fewer than 65,000
 - More than 65,000
 - There are no published estimates of disease prevalence
- What is the most common ocular cause of neurotrophic keratitis?**
 - Ocular surgery
 - Herpetic infections
 - Laser vision correction
 - Contact lens wear
- The stepwise approach developed by Sacchetti and Lambiase is commonly used to treat patients with neurotrophic keratitis. Which of the following describes the first step?**
 - Stage the disease and treat any associated ocular surface disease or comorbidities
 - Perform a direct corneal neurotization procedure
 - Perform a confirmatory corneal sensitivity test

Neurotrophic Keratitis:

New Approaches to Manage Disease and Improve Patient Satisfaction

NEUROTROPHIC KERATITIS: DIFFERENTIAL DIAGNOSIS, TREATMENT OPTIONS, AND CASE DISCUSSIONS

The introduction of a breakthrough therapy that heals this rare disease signals a new treatment paradigm.

MARJAN FARID, MD; TERRY KIM, MD; AND FRANCIS S. MAH, MD

Neurotrophic keratitis is classified as a rare disease in the United States, where it affects fewer than 65,000 individuals, based on estimated disease prevalence.¹ It is a progressive, degenerative disease caused by impairment of trigeminal innervation, leading to corneal epithelial breakdown, compromised healing, and corneal ulceration, melting, perforation, and vision loss.¹

Several conditions can lead to impairment of trigeminal innervation, and they can be categorized as follows:

- **Ocular.** One of the most common ocular causes of neurotrophic keratitis is infection, more specifically, postherpetic infections, whether it is herpes simplex or herpes zoster. Ocular surgery, such as laser vision correction procedures, may lead to neurotrophic keratitis, as can chronic contact lens wear. Other causes include chemical and physical burns, abuse of topical anesthetics, drug toxicity, and chronic ocular surface injury.²
- **Systemic.** Diabetes is one of the most common systemic etiologies of neurotrophic keratitis. Analogous to diabetic

neuropathy that may occur in the feet of a diabetic patient, neurotrophic keratitis can manifest in the cornea, as the nerves in the cornea are affected by a similar pathophysiology. Other systemic conditions associated with neurotrophic keratitis include multiple sclerosis, vitamin A deficiency, leprosy, and amyloidosis.²

- **Central nervous system.** Postneurosurgical procedures, most commonly procedures for trigeminal neuralgia and acoustic neuromas, may cause neurotrophic keratitis, and stroke, neoplasm, aneurysms, and degenerative disorders are also associated with this disease.²

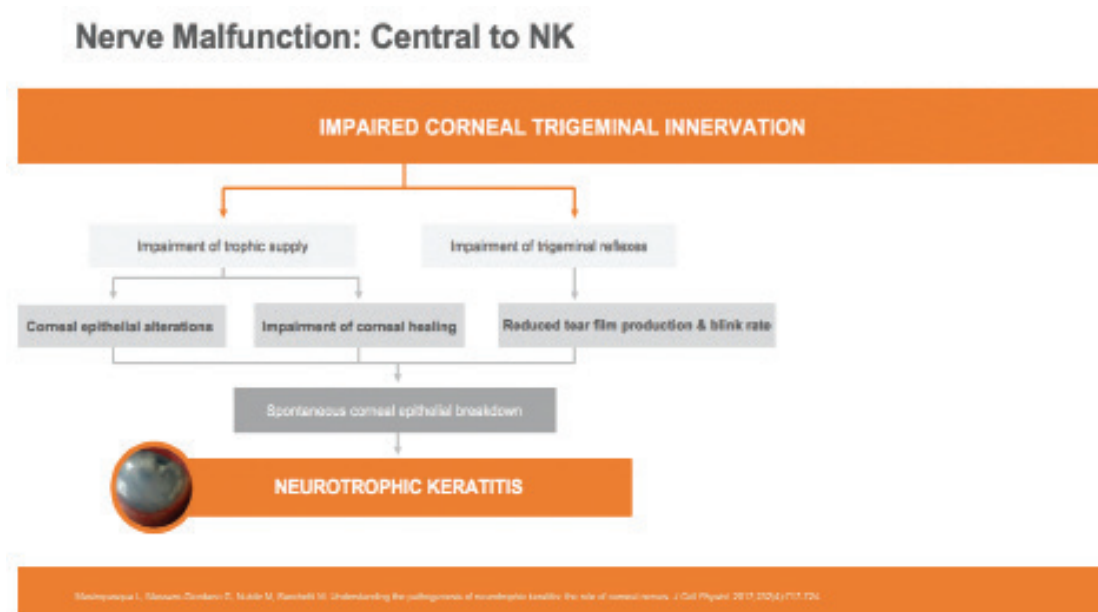
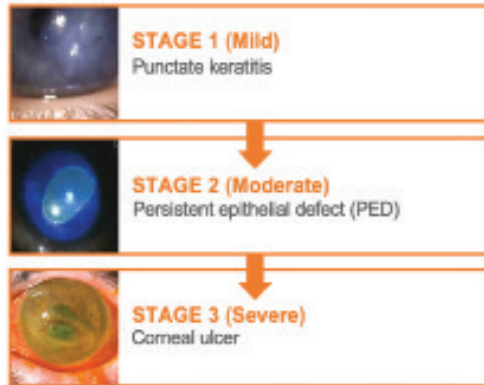


Figure 1. Neurotrophic keratitis begins with impaired corneal trigeminal innervation and branches out to impairment of the trophic supply or impairment of the trigeminal reflexes.

NK Is a Degenerative Disease¹

The Mackie Classification Represents One Way to Assess NK Progression^{2,3}



- Some vision loss can potentially be seen **in all stages of NK³**
- If untreated, **moderate NK progresses to severe disease** with associated risks of **profound vision loss** resulting from scarring and corneal perforation³

1. Quattrone SE, et al. Neurotrophic keratitis. *Prog Retin Eye Res*. 2012;36:107-134.

2. Sweeney P, et al. *Neurotrophic Keratitis*. *Ophthalmology*. 2013;120:111-120.

3. Saito H, et al. *Neurotrophic Keratitis*. *Ophthalmology*. 2013;120:111-120.

Figure 2. The Mackie classification is one method for assessing neurotrophic keratitis progression.

- **Genetic.** Although less common than the conditions in the first three categories, some genetic disorders are associated with neurotrophic keratitis, including Riley-Day syndrome, Goldenhar-Gorlin syndrome, and Mobius syndrome, as well as familial corneal hypoesthesia.²

Nerve malfunction is central to neurotrophic keratitis (Figure 1).³ It begins with impaired corneal trigeminal innervation and branches out to impairment of the trophic supply, which results in corneal epithelial alterations and impairment of corneal healing, or impairment of the trigeminal reflexes, which results in reduced tear film production and blink rate. These factors eventually lead to spontaneous corneal epithelial breakdown, which starts the process of neurotrophic keratitis.

Because neurotrophic keratitis is a degenerative disease,² we need to employ a classification system to identify the stages of progression in order to determine when to intervene with appropriate therapies.

The Mackie classification system divides neurotrophic keratitis into three stages (Figure 2)^{4,5}:

- **Stage 1** is considered mild neurotrophic keratitis, which commonly manifests as punctate keratitis and surface epitheliopathy. If stage 1 disease goes untreated, it can progress to corneal vascularization and corneal scarring.
- **Stage 2** represents moderate disease, which manifests as a persistent epithelial defect.
- **Stage 3** represents severe neurotrophic keratitis with corneal ulceration.

Even in mild Stage 1 disease, there is potential for vision loss, and if left undiagnosed and untreated, neurotrophic keratitis can progress quickly from mild to moderate to severe.⁵ In the moderate to severe stages, patients are at risk not only for profound vision loss but also for severe sequelae, such as corneal scarring and corneal perforation.⁵

DIAGNOSTIC CONSIDERATIONS

A thorough patient history aimed at identifying risk factors for neurotrophic keratitis is critical.⁶ In some cases, a clinician may have to take a step back to reevaluate a patient's history if the current therapy doesn't seem to be working. For example, if you're treating what you believe is dry eye but observing no or minimal response, a closer look at the patient's medical, ocular, and medication history may reveal an underlying risk factor, such as previous herpetic infections or previous ocular surgeries that can predispose a patient to neurotrophic keratitis.

Corneal sensitivity testing is a key step in diagnosing neurotrophic keratitis and differentiating it from other conditions that may present with epitheliopathy or decreased corneal sensation.⁷ We recommend building it into your corneal examination. Cochet-Bonnet esthesiometry is available as a quantitative test, but it is more commonly used in basic research and clinical trial settings and may not be practical in clinical practice.

Qualitatively, you may use a cotton swab, a cotton wisp, nonwaxed dental floss, or the tip of a tissue, most of which are readily available in an examination lane. Be sure to test the normal eye before the affected eye, and if you will be evaluating a patient whom you suspect has neurotrophic keratitis, remember to test corneal sensitivity before your technician instills anesthetic drops to measure IOPs.

Basic scoring scales can be used for these simple tests, and they typically are descriptive in terms of the degrees of corneal desensitization—normal, hypoesthesia, or anesthesia, for example. Or they may be binary—sensation versus no sensation or slightly diminished versus complete loss. Corneal sensitivity testing, which takes only seconds, can be an important step toward early intervention and ultimately preventing further morbidity and complications from neurotrophic keratitis.

Be aware that signs and symptoms may not correlate. Patients with advanced disease may be asymptomatic because of a marked decrease in corneal sensation.² If a patient has an epithelial defect with significant staining but absolutely no discomfort—stain with no pain—the diagnosis is obviously neurotrophic keratitis. Another finding that suggests neurotrophic keratitis as opposed to dry eye is corneal staining that is more prominent than conjunctival staining.

Microbiological examination of large persistent epithelial defects will help you rule out bacterial, fungal, or viral infection as a potential cause for the defects.⁴

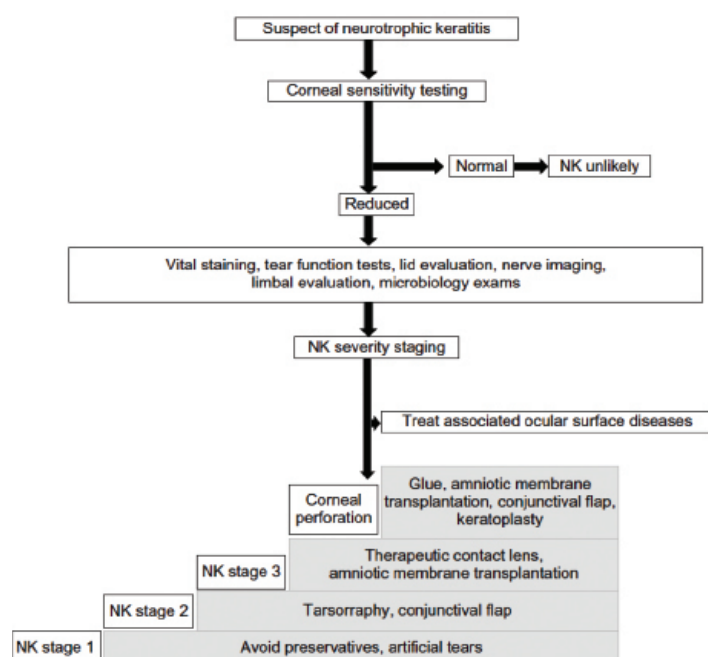


Figure 3. A stepwise approach to diagnosing and treating neurotrophic keratitis.

Evaluation for systemic immune disorders also should be considered in light of some of the other conditions associated with neurotrophic keratitis.⁴

Not only can some chronic comorbidities worsen the prognosis for a case of neurotrophic keratitis, but they can also confound the diagnosis. These conditions include dry eye, anterior and posterior blepharitis, exposure keratitis, topical drug toxicity, mild chemical injury, contact lens-related disorder, and limbal stem cell deficiency.¹

TREATMENT ALGORITHMS

Similar to dry eye patients, patients with neurotrophic keratitis will vary and their treatment will require a dynamic approach. One of the universal concepts is to remove any additional insults to the ocular surface, such as topical drops that contain preservatives.

Clinicians who may not be familiar with diagnosing and treating neurotrophic keratitis may find a stepwise approach published by Sacchetti and Lambiase helpful (Figure 3).

They recommend if you have a suspicion of neurotrophic keratitis, you should perform a confirmatory corneal sensitivity test, either qualitative or quantitative. If sensitivity is normal, it's unlikely your patient has neurotrophic keratitis. If sensitivity is reduced, further testing is warranted, including vital staining with rose bengal or lissamine green, tear function, evaluation of the eyelids to rule out other conditions that can cause similar findings, corneal nerve imaging, evaluation of the corneal limbus, and microbiological examinations to rule out infection.

The next step is to stage the disease and treat any associated ocular surface disease or comorbidities. For Stage 1 neurotrophic keratitis, the recommendation is to lubricate the cornea with artificial tears or ointments and avoid topical medications that contain preservatives, which can be toxic. Treatment for Stage 2 may involve tarsorrhaphy or a conjunctival flap. Treatment for Stage 3 may require a therapeutic contact lens and/or amniotic membrane transplantation (AMT). A corneal perforation will necessitate corneal gluing, AMT, conjunctival flap, or keratoplasty.

Figure 4 shows a categorized approach to the treatment options that are available for neurotrophic keratitis, depending on stage of severity. Note that these treatments are not mutually exclusive.¹⁻³

Under topical medications, in addition to artificial tears, autologous serum eyedrops are recommended, and some clinicians

are using platelet-derived growth factors to make tears. There also may be a role for corticosteroid and antibiotic therapy, and we now have cenegelein-bkbj ophthalmic solution 0.002% (Dompé).

In-office procedures, such as therapeutic bandage contact lenses and punctal occlusion can be helpful. Nonsurgical eyelid closure, whether by cyanoacrylate gluing of the eyelids or a botulinum toxin type-A (Allergan) tarsorrhaphy to close the upper eyelid, is another option. Multilayer AMT can be performed in the office, either with a bandage contact lens or with a carrier ring, and there are also tissue adhesives.

NK Treatment Options¹⁻³

Treatments are typically used according to NK stage/severity but are not mutually exclusive of one another. The table is not an exhaustive list of all available treatment options.

Topicals	In-Office Procedures	Surgical Intervention
<ul style="list-style-type: none"> Artificial tears Corticosteroids Autologous serum eye drops Antibiotics Cenegelein-bkbj ophthalmic solution 0.002% [20 mcg/ml] 	<ul style="list-style-type: none"> Therapeutic contact lenses Punctal occlusion Non-surgical eyelid closure Multilayer amniotic membrane transplantation (AMT) Tissue adhesives 	<ul style="list-style-type: none"> Tarsorrhaphy Conjunctival flap Corneal transplant Direct neurotization Sutured AMT

1. Sacchetti R, Lambiase D, et al. Neurotrophic keratitis. *Prog Retin Eye Res*. 2018;66:107-121.
 2. Lambiase D, Sacchetti R, et al. Neurotrophic keratitis: A review of the pathogenesis and treatment. *J Ocul Pharmacol Ther*. 2017;32:717-724.
 3. Lambiase D, Lambiase G. Diagnosis and management of neurotrophic keratitis. *Curr Opin Ophthalmol*. 2017;32:1047-1055.

Figure 4. Treatment options for neurotrophic keratitis.

PUTTING A STEPWISE ALGORITHM INTO PRACTICE

Terry Kim, MD

A stepwise algorithm for treating neurotrophic keratitis typically advances from a conservative approach to more aggressive management. For example, most patients diagnosed with Stage 2 neurotrophic keratitis have already been treated with topical lubrication and probably a bandage contact lens. This is an indication to start topical cenegeim-bkbj 0.002% 6 times a day for 8 weeks.

I see patients when they start cenegeim-bkbj therapy to make sure they understand their instructions, and depending on the severity of their disease, I may monitor them every few days for the first week or two. Once I see that the defect is healing, I decrease the frequency of follow-up visits.

It is appropriate for patients to use concomitant topical lubrication while using cenegeim-bkbj, but I typically don't apply a bandage contact lens or amniotic membrane at that point.

If I suspect a patient has Stage 1 neurotrophic keratitis, I use a cotton-tipped applicator to perform confirmatory testing, which will determine if there is decreased corneal sensitivity. Typically, I start therapy with lubrication and wait to see if they respond; however, I have a low threshold for starting topical cenegeim-bkbj therapy in these cases.

For Stage 3 neurotrophic keratitis, my algorithm changes. I am much more aggressive. These are the patients who will need either lateral or central permanent tarsorrhaphy. I have referred some of these patients to my oculoplastic colleagues for corneal neurotization, but these procedures are long and complex, so typically patients need something to temporize them before they go through therapy.

When surgical intervention is required for the more severe, advanced stages of neurotrophic keratitis, the options include a surgical tarsorrhaphy, a conjunctival flap procedure such as a Gundersen flap, a partial Gundersen flap, corneal transplantation, or sutured AMT. More recently, there have been reports of performing direct corneal neurotization procedures.⁸ This is being offered by the oculoplastic service at Duke University.

In the pages that follow, we focus on cenegeim-bkbj, a novel recombinant human nerve growth factor (NGF), which is the only topical medication approved by the FDA for treating neurotrophic keratitis.

ROLE OF NERVE GROWTH FACTOR

Endogenous NGF is essential for the development, survival, growth, and differentiation of corneal cells. It is believed to support corneal integrity through several mechanisms.

- **Corneal innervation.** Endogenous NGF stimulates the regeneration and survival of the sensory nerves.^{1,9}

Clinical Trials: Study Criteria

Cenegeim-bkbj 20 mcg/mL

Main exclusion criteria

- Infection, inflammation, other ocular disease requiring topical treatment
 - Glaucoma patients were switched to systemic meds during the study
- Severe blepharitis or MGD
- Prior surgical treatment for NK
 - Exception for AMT performed > 6 weeks prior or membrane disappeared > 2 prior
- Stromal involvement in posterior third, corneal melting, or perforation in study eye

1. ClinicalTrials.gov Identifier: NCT01750466. 2. ClinicalTrials.gov Identifier: NCT01714147

Figure 5. Main exclusion criteria in the US and European clinical trials.

- **Tear secretion.** It binds receptors on the lacrimal gland and promotes sensory-mediated reflex tear secretion.^{3,10}
- **Cell proliferation and differentiation.** It stimulates proliferation, differentiation, and survival of corneal epithelial cells.³

The active ingredient of cenegeim-bkbj is structurally identical to the NGF protein that is produced in the human body, including in the ocular tissues.¹¹ Naturally occurring neurotrophins are responsible for differentiation, growth, and maintenance of neurons.¹² The regenerative potential of NGF was discovered by Nobel prize-winning scientists in the early 1950s.¹² Its therapeutic potential in ophthalmology was confirmed when Dompé's research and development team created cenegeim-bkbj, the first topical biologic medication approved in ophthalmology and the first treatment specifically indicated for neurotrophic keratitis.

DEMONSTRATED SAFETY AND EFFICACY

Cenegeim-bkbj recombinant human NGF is about 10 times more potent than murine NGF based on *in vitro* studies. A phase 1 study of 74 healthy subjects reported favorable safety and tolerability with no immunogenicity and no significant changes in serum NGF.¹³ The resulting product is a more potent patient-compatible NGF.

Clinical trials of cenegeim-bkbj ophthalmic solution 0.002% in the United States and Europe enrolled the largest combined population of neurotrophic keratitis patients ever studied in controlled trials.^{5,14}

In the US trial (NGF0214), 48 patients with unilateral or bilateral disease were enrolled at 11 clinical centers where they were randomly assigned to vehicle or cenegeim-bkbj 20 mcg/mL. The duration of follow-up was 24 weeks. The

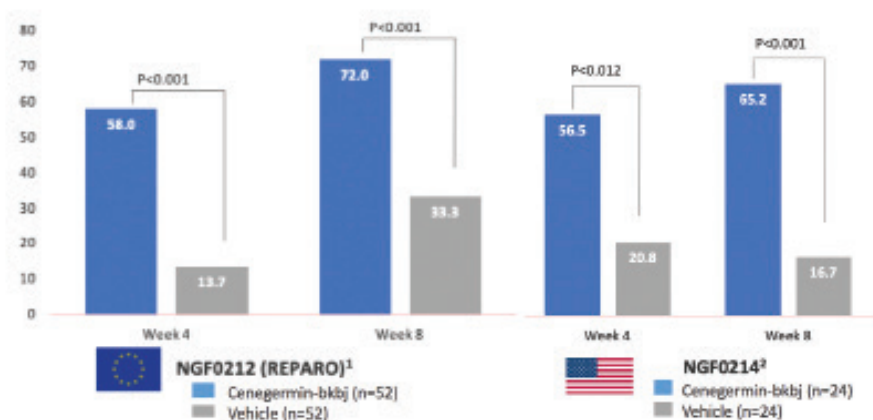


Figure 6. At week 8, complete corneal healing was achieved in up to 72% of patients treated with cenegermin-bkbj.

Clinical Trials: Pooled Safety Report

Cenegermin-bkbj 20 mcg/ml

- No serious adverse reaction related to the treatment occurred in any clinical trials
- The majority of adverse reactions were mild and transient ocular reactions that did not require treatment discontinuation or any corrective treatment



Source: Data on file, pooled analysis of NGF0212/REPARO and NGF0214

1. Berthel E, Lambertz A, Kave P, et al. Phase II Randomized, Double-Masked, Vehicle-Controlled Trial of Recombinant Human Keratinocyte Growth Factor for Neurotrophic Keratitis. *Ophthalmology*. 2018;125(12):2042-2050. doi:10.1016/j.ophtha.2018.05.018

Figure 7. The majority of adverse reactions were mild or transient ocular reactions that did not require stopping treatment or any corrective measures.

endpoint—complete corneal healing defined as 0.0 mm maximum diameter of fluorescein staining in the lesion area—was at 8 weeks. Vehicle-treated patients who were not healed at week 8 were switched to the treatment arm.

In Europe, the REPARO study (NGF0212) enrolled 156 patients who had unilateral disease, and randomly assigned them to vehicle, cenegermin-bkbj 10 mcg/mL, or cenegermin-bkbj 20 mcg/mL. As in the US trial, the endpoint in Europe was 8 weeks; however, the duration of follow-up in Europe was 48 weeks. In Europe, investigators did allow for a small area of staining; whereas, in the United States, the bar was set higher, with 0.0 mm fluorescein staining permitted.

Study participants were adults with stage 2/3 neurotrophic keratitis (in one eye only and without perforation). They had to be nonresponsive to existing treatments and have decreased corneal sensitivity. Figure 5 summarizes the main exclusion criteria.

In the US trial, the majority of patients had Stage 2 moderate disease, and the underlying cause of neurotrophic keratitis in more than one-third of the patients enrolled was herpetic eye disease.

In both the US trial and the European trial, more than half of the patients treated with cenegermin-bkbj (56.5% and 58.0%, respectively) were completely healed by week 4. By week 8, up to 72% of patients were completely healed (Figure 6).

Furthermore, in the European trial, 80% of patients who achieved complete corneal healing after just one 8-week cenegermin-bkbj treatment cycle were still healed after 1 year.

These data show that with cenegermin-bkbj we now have the ability to heal neurotrophic keratitis. What's more, that 80% statistic is a motivating factor for patients to continue with cenegermin-bkbj therapy every 2 hours, 6 times a day for the full 8 weeks.

There were no serious adverse reactions related to treatment with cenegermin-bkbj (Figure 7). The majority of adverse reactions were mild or transient ocular reactions that did not require treatment discontinuation or any corrective treatment. The most common adverse reaction was eye pain following instillation, which was reported in approximately 16% of patients. Although the percentage of patients reporting eye pain is low, we tell our patients to expect some discomfort, usually around week 2 or week 3. Other less significant adverse reactions included corneal deposits, foreign body sensation, ocular hyperemia, ocular inflammation, and tearing.

Cenegermin-bkbj is neither systemically absorbed nor immunogenic. In phase 1 studies in healthy patients at doses up to 180 µg/mL, serum concentrations of NGF did not differ from basal levels. In phase 1/2 trials, NGF serum levels were below the lower level of quantification in almost all patients. No systemic immunogenicity was detected in any of the clinical studies. In addition, endogenous NGF has a very low residence time in the eye. Being hydrophilic, it is quickly removed with the tear flow.

In the majority of patients across the two clinical trials, cenegermin-bkbj ophthalmic solution 0.002% was well tolerated and more effective than vehicle in promoting complete corneal healing of moderate or severe neurotrophic keratitis (Figure 8).

CONCLUSION

Cenegermin-bkbj ophthalmic solution 0.002% represents a significant paradigm shift in terms of treatment for neurotrophic keratitis. In clinical trials, up to 72% of patients with Stage 2/3

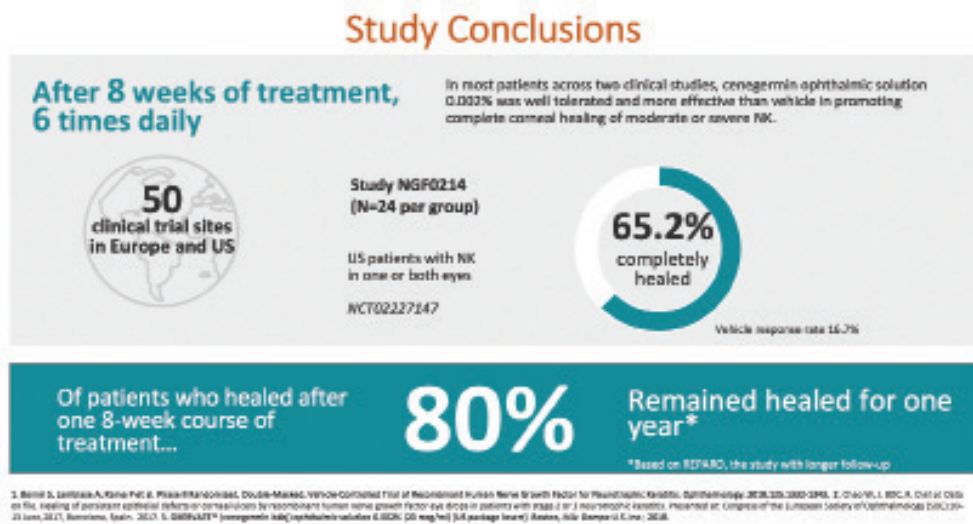


Figure 8. Of the patients who healed after one 8-week course of cenegermin-bkbj, 80% remained healed after 1 year.

neurotrophic keratitis were completely healed after an 8-week course of therapy, and of those patients, 80% remained healed for another 48 weeks. This is a potential cure for our patients with neurotrophic keratitis. ■

- 1998;338(17):1174-1180.
13. Ferrari MP, Mantelli F, Sacchetti M, et al. Safety and pharmacokinetics of escalating doses of human recombinant nerve growth factor eye drops in a double-masked, randomized clinical trial. *BioDrugs*. 2014;28(3):275-283.
14. Pflugfelder S, Massaro-Giordano M, Perez V, et al. Topical recombinant human nerve growth factor (cenegermin) for neurotrophic keratopathy: a multicenter randomized vehicle-controlled pivotal trial. *Ophthalmology*. 2020;127(1):14-26.

1. Sacchetti M, Lambiase A. Diagnosis and management of neurotrophic keratitis. *Clin Ophthalmol*. 2014;8:571-579.
2. Dua HS, Said DG, Messmer EM, et al. Neurotrophic keratopathy. *Prog Retin Eye Res*. 2018;66:107-131.
3. Mastropasqua L, Massaro-Giordano G, Nubile M, et al. Understanding the pathogenesis of neurotrophic keratitis: the role of corneal nerves. *J Cell Physiol*. 2017;232(4):717-724.
4. Semeraro F, Forbice E, Romano V, et al. Neurotrophic keratitis. *Ophthalmologica*. 2014;231(4):191-197.
5. Bonini S, Lambiase A, Rama P, et al.; for the REPARO Study Group. Phase II randomized, double-masked, vehicle-controlled trial of recombinant human nerve growth factor for neurotrophic keratitis. *Ophthalmology*. 2018;125(9):1332-1343.
6. Versura P, Giannaccare G, Pellegrini M, et al. Neurotrophic keratitis: current challenges and future prospects. *Eye Brain*. 2018;10:37-45.
7. Milner MS, Beckman KA, Luchs JJ, et al. Dysfunctional tear syndrome: dry eye disease and associated tear film disorders – new strategies for diagnosis and treatment. *Curr Opin Ophthalmol*. 2017;27 Suppl 1:3-47.
8. Wisely CE, Rafailov L, Cypen S, et al. Clinical and morphologic outcomes of minimally invasive direct corneal neurotization. *Ophthalmic Plast Reconstr Surg*. 2020 Feb 6. [Epub ahead of print]
9. Müller LJ, Marfurt CF, Kruse F, et al. Corneal nerves: structure, contents and function. *Exp Eye Res*. 2003;76(5):521-542.
10. Muzi S, Colafrancesco V, Sornelli F, et al. Nerve growth factor in the developing and adult lacrimal glands of rat with and without inherited retinitis pigmentosa. *Cornea*. 2010;29(10):1163-1168.
11. Voelker R. New drug treats rare, debilitating neurotrophic keratitis. *JAMA*. 2018;320(13):1309.
12. Lambiase A, Rama P, Bonini S, et al. Topical treatment with nerve growth factor for corneal neurotrophic ulcers. *N Engl J Med*.

CASE STUDIES

PERSISTENT EPITHELIAL DEFECTS

PRESENTED BY MARJAN FARID, MD

CASE 1: STAGE 2 NK—PERSISTENT EPITHELIAL DEFECT

This 75-year-old man with a nonhealing corneal epithelial defect in the left eye was referred to my practice by a colleague who had been treating him for some time. The patient had LASIK in both eyes 20 years prior, and he had a history of herpes zoster ophthalmicus in the left eye. The patient reported that nearly a year ago he had a similar episode of what he called a corneal abrasion in that eye, which healed after 2 weeks of aggressive lubrication and antibiotic drops.

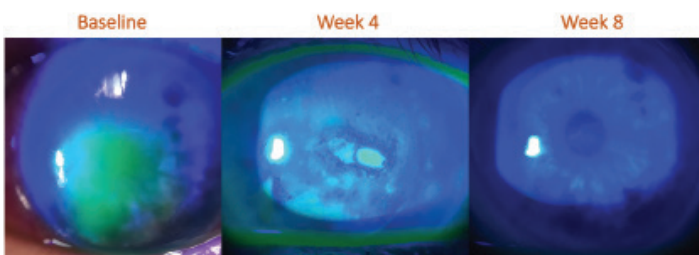


Figure 1. Case 1: After an 8-week course of cenegermin, the persistent epithelial defect was completely healed.

The patient's history revealed several significant risk factors for neurotrophic keratitis: herpes zoster, LASIK, and a corneal abrasion that took 2 weeks to heal. In fact, the latter probably was not a corneal abrasion at all but the patient's first episode of epithelial breakdown from neurotrophic keratitis.

The referring physician had applied a bandage contact lens over a self-retaining amniotic membrane. He had tried fresh frozen amniotic membrane, as well, and had prescribed autologous serum eyedrops. Despite several weeks of these therapies, the epithelial defect persisted.

When I saw the patient, he was using antibiotic eyedrops, preservative-free artificial tears, and an oral antiviral medication, which I believe was reasonable in case the patient was experiencing a recurrence of the shingles.

Corneal sensitivity testing with a cotton wisp revealed complete anesthesia of the left eye. This was a classic case of neurotrophic keratitis, Stage 2.

At baseline (Figure 1, left), staining revealed a central epithelial defect without infiltrates. The patient started an 8-week course of treatment with cenegermin. By week 4 (Figure 1, center), the size of the epithelial defect had decreased significantly, and by week 8 (Figure 1, right), the lesion had fully healed.

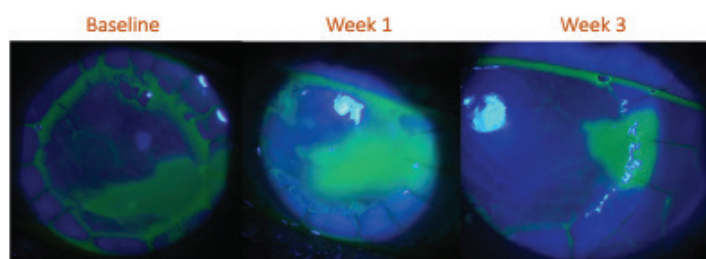


Figure 2. Case 2: By week 3, the epithelial defect is noticeably smaller, and the graft edge is very smooth, with no step off.

Not only had the epithelial defect completely resolved, but the irregular epitheliopathy and the punctate keratitis was also gone, leaving a very smooth epithelium. The patient's vision also benefited.

About a year after completing cenegermin therapy, the cornea is still completely healed and smooth with minimal use of preservative-free artificial tears.

CASE 2: NONHEALING EPITHELIAL DEFECT FOLLOWING PKP

A 78-year-old woman presented to me with a bacterial corneal ulcer with poor healing that required a therapeutic penetrating keratoplasty (PKP). Two months after the transplant, the cornea still had not healed, and a large epithelial defect developed.

I prescribed antibiotic and steroid eyedrops to prevent rejection following PKP and applied therapeutic bandage contact lenses as well as a self-retaining amniotic membrane. The patient was using preservative-free artificial tears. Suspecting underlying herpetic eye disease, perhaps a recurrence on the graft, I started an oral antiviral.

Corneal sensitivity was decreased, but it was difficult to determine if this was from neurotrophic keratitis or if it was a result of delayed

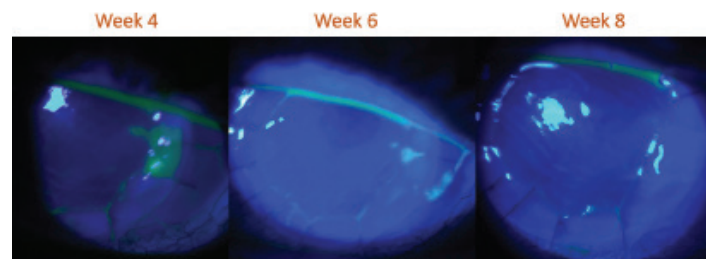


Figure 3. Case 2: By week 8, the epithelial defect was completely resolved.

innervation of the graft following PKP. We know it takes 6 months to reinnervate a LASIK flap, so in a corneal transplant, particularly a full-thickness one, I assume it would take even longer.

At baseline (Figure 2, left), which was 2 months following PKP, a large, nonhealing epithelial defect was present, and I decided to start the patient on cenegermin. It sometimes takes a few weeks to acquire the medication, so in the interim, I employed various supportive measures, including bandage contact lenses.

Only 1 week after starting cenegermin (Figure 2, center), the epithelial defect had already decreased in size. By week 3 (Figure 2, right), it became even smaller. There was small triangular shape within the graft, and the graft edge was very smooth with no step off.

At week 4 (Figure 3, left), the defect was smaller, and at week 6 (Figure 3, center), it was a pinpoint defect. By week 8 (Figure 3, right), the defect was completely healed, with minimal staining, and it has remained closed for about 9 months.

This is an example of a more severe case of neurotrophic keratitis, and I believe if I hadn't chosen to use cenegermin, scarring would have ensued and potentially would have ruined the long-term graft survivability. ■

CASE STUDIES

NK: DRY EYES AND LASIK

PRESENTED BY FRANCIS S. MAH, MD

CASE 1: STAGE 1 NK (DIFFERENTIATING FROM DRY EYE)

This 45-year-old woman with diabetes had a history of diabetic neuropathy and more recently diabetic retinopathy. She is status post pars plana vitrectomy. She was referred to me by a retina colleague for punctal plugs to treat severe, unresponsive dry eyes.

The patient reported ocular irritation, tearing, itching, light sensitivity, and mainly blurred vision. Her symptoms were constant, and they worsened throughout the day. She felt uncomfortable driving, and she could not read. She said she can't do what she feels she should be able to do.

The patient's therapeutic history (Figure 1) showed she had been treated aggressively for dry eyes. At the time of the visit, she

Current Therapy

➤Has tried the following and found no symptom relief:

- cyclosporine ophthalmic emulsion 0.05%
- lifitegrast ophthalmic solution 5%
- topical steroids
- topical antibiotic ointment and drops

➤Using warm compresses and lid scrubs

➤Taking 4000 IU omega-3 fatty acids

➤Plugs did not help: OD is gone, OS present but states OS is worse

➤Has used and is using OCT PF AT without relief

Figure 1. Case 1: The patient was treated aggressively for dry eyes.

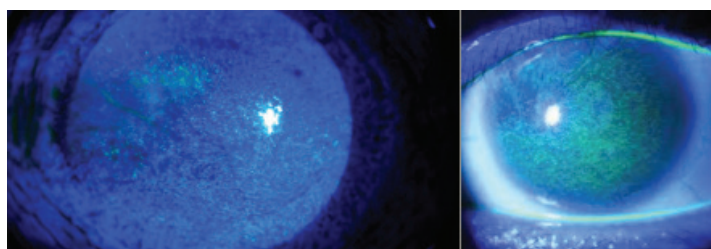


Figure 2. Case 1: Note the whorled pattern, which is not typical of dry eyes.

reported using over-the-counter preservative-free artificial tears with no relief.

At first glance (Figure 2), this appears to be a case of severe dry eye, but the whorled pattern of staining was not typical of classic dry eye. Because of this, corneal sensitivity testing for neurotrophic keratitis was indicated.

I diagnosed bilateral Stage 1 neurotrophic keratitis and prescribed cenegermin. Within 2 weeks of starting the medication, the patient's vision improved. She was extremely happy and said she felt safer driving. She completed the 8-week course of drops 6 times a day, and the epithelium has been intact for more than a year.

In cases such as this one, you may look at the staining pattern quickly, gloss over the history, and continue to treat aggressively for dry eyes. But when you perform that one simple test with a cotton wisp or a corner of a tissue and find decreased corneal sensitivity, the diagnosis and treatment options change dramatically.

For some clinicians, the question may remain: How do you distinguish between severe dry eye and early neurotrophic keratitis? There is a fine line between the two. Some patients who have long-standing dry eye simply stop feeling their corneas. Therefore, in addition to prescribing cenegermin, I would apply a self-retained amniotic membrane, especially as a bridge therapy to protect the ocular surface until we receive the cenegermin.

Another approach to differentiating neurotrophic keratitis from dry eye is to apply a contact lens. It seems counterintuitive, but if a patient achieves some relief with a contact lens, I think more about dry eyes than neurotrophic keratitis. Generally, patients with neurotrophic keratitis tend to not complain.

I would also stain the conjunctiva with lissamine green or rose bengal. Many patients who have chronic dry eyes have devitalized epithelium on their conjunctival surface. This can be a helpful differentiator in terms of determining the appropriate treatment path for these two different conditions. Also, if filaments are present, in general, I'd hedge more toward a dry eye diagnosis.

CASE 2: LASIK NK

This 53-year-old woman with a large central corneal abrasion in the right eye was referred to me by a neuro-ophthalmologist, whom she was consulting for facial pain.

During the management and referrals for her right-sided facial pain, the patient underwent uncomplicated bilateral LASIK surgery. Two months after the LASIK surgery, she was diagnosed with right-sided trigeminal neuralgia. A rhizotomy of her ganglion to

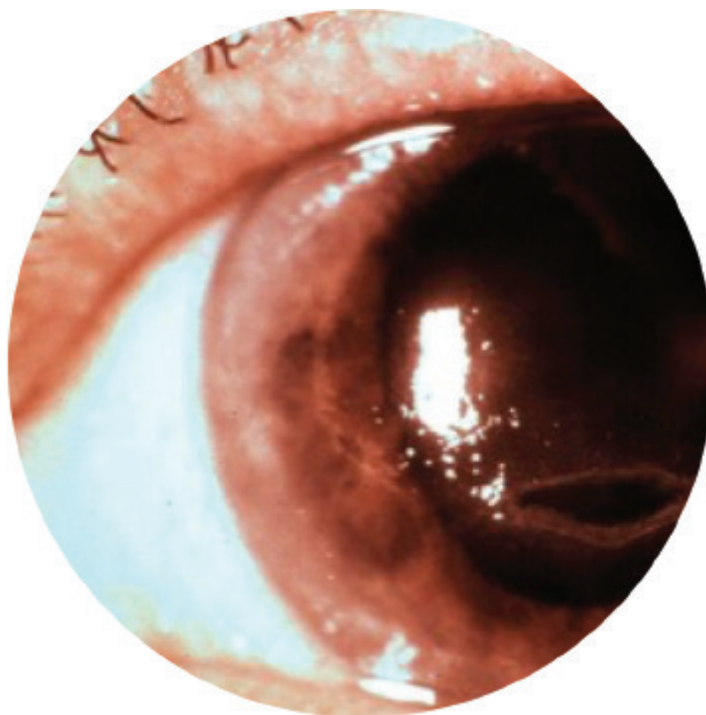


Figure 3. Case 2: A large central corneal abrasion in a patient with right-sided facial and eye numbness.

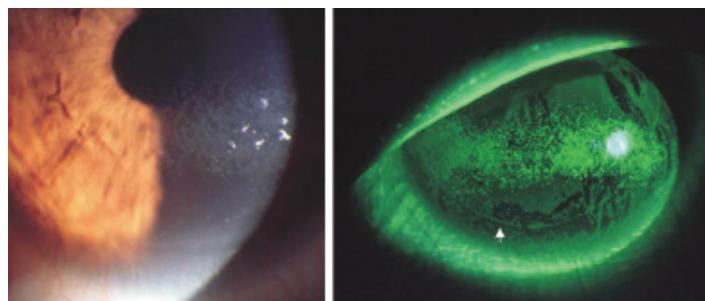


Figure 4. Case 2: After treatment with erythromycin ointment 4 times a day for 2 weeks, the abrasion healed.

relieve the trigeminal neuralgia was unsuccessful and resulted in right-sided facial and eye numbness.

The patient reported that her central vision becomes hazy as the day progresses. She uses artificial tears, which help her vision for a brief period. She feels no pain, but later in the day, her vision becomes so poor that she covers her right eye. The patient was using ciprofloxacin eye drops 3 or 4 times a day, as prescribed by the neuro-ophthalmologist.

Figure 3 shows the epithelial defect inferiorly in the right eye.

The patient's visual acuity was 20/40 in the right eye (no improvement with pinhole). Her left eye, which is her unaffected eye was 20/40 (20/20, with pinhole).

The patient had no corneal sensation and no complaints of pain or discomfort, despite the large epithelial defect. I diagnosed Stage 2 neurotrophic keratitis.

I prescribed erythromycin ointment 4 times a day in the affected eye, and the abrasion healed within 2 weeks (Figure 4).

The issue with an ointment is that it blurs the vision. This patient has good quality vision, and she needed her eyes for her work. She did not want to use the ointment.

Whenever we tried to decrease the ointment use and add aggressive topical preservative-free gels and preservative-free artificial tears, the epithelium would break down. Over 12 months, each time she stopped the ointment, another abrasion would form. She would come in because her vision was reduced not because of pain.

I also tried self-retained amniotic membrane. The epithelium healed but kept breaking down when the patient decreased the

ointment use, because she couldn't see through it. She was even fitted for a scleral contact lens, but she couldn't tolerate it. We also tried tarsorrhaphy, but the patient did not like it.

When cenegermin was approved, I discussed the treatment with the patient and almost immediately we decided to try it. The day after the patient started cenegermin, she asked the ophthalmic surgeon to remove the tarsorrhaphy.

After 4 weeks, the cornea was completely healed. She continued cenegermin for 8 weeks. After treatment with cenegermin, we've been able keep her cornea healthy for more than a year with only artificial tears. At her last visit, her visual acuity was 20/25. ■

CASE STUDIES

'EASY DIAGNOSIS'

PRESENTED BY TERRY KIM, MD

A 78-year-old woman transferred her care to our practice and asked for a second opinion regarding her cornea. Her left eye was symptomatic with constant discomfort, "like a soft contact lens is scratching my eye," as she described it, along with worsening vision.

She has a history of poor vision in her right eye since childhood, owing to refractive amblyopia. She has a medical history of diabetes with peripheral neuropathy, and she has pseudoexfoliative glaucoma in both eyes. At her initial visit, she had a bandage contact lens on her left eye. Figure 1 summarizes her ocular history.

The patient has been going to the fellow clinic for 2 months for bandage contact lens placement and replacement. Her visual acuity is counting fingers at 5 feet in the right eye and 20/70 in the affected left eye. Intraocular pressures are 19 mm Hg in the right eye and 20 mm Hg in the left eye.

Slit lamp examination of the left eye with a broad-beam light revealed a distinct lesion in the midperipheral inferior cornea (Figure 2). This appeared to be a discrete epithelial defect, measuring 4 mm to 5 mm

horizontally and 1 mm to 2 mm vertically. Rolled epithelial edges were also visible. The lesion was fairly close to the central cornea, which is the reason why the patient's visual acuity was affected adversely.

While the clinical presentation at this point probably didn't indicate it, I thought confirmatory testing was warranted, even for Stage 1 neurotrophic keratitis, to catch the disease process early and avoid progression. A cotton wisp test confirmed decreased sensitivity, and I diagnosed Stage 2 neurotrophic keratitis. In this case, the distinct defect with rolled edges suggested the disease could progress to Stage 3 fairly quickly if not addressed promptly. I prescribed an 8-week course of topical cenegermin 6 times a day.

If you anticipate having to wait to receive the medication, I recommend starting an adjunctive therapy in the interim, which was the case for this patient. She had been treated with numerous topical medications and bandage contact lenses, and the defect persisted. Therefore, I would advocate for placement of a self-retained amniotic membrane to temporize her case before instituting cenegermin. ■

Ocular History

2/2018 phaco with IOL

2/28/2018 emergent CPC for increased IOP

CME OS: S/P multiple IV VEGF injections OS

Meds:

- Bimatoprost 0.01% OU QHS
- Brinzolamide/brimonidine 1%/0.2% TID OD
- Prednisolone acetate 1% TID OS
- Moxifloxacin TID OS
- Acyclovir 400 mg PO BID
- Artificial tears PF AT PRN

Figure 1. This patient requested a second opinion regarding constant corneal discomfort.

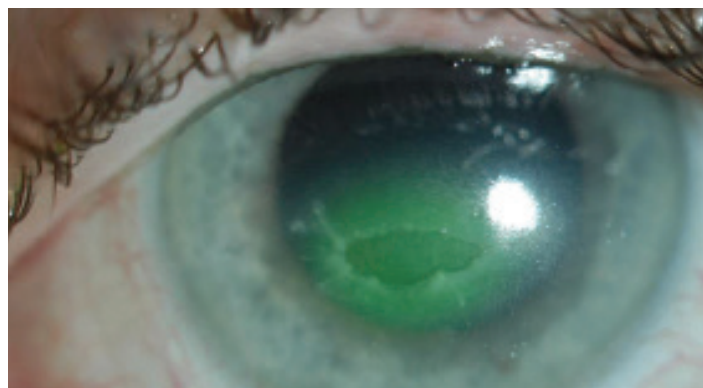


Figure 2. A distinct epithelial defect and the beginning of rolled edges are apparent under slit lamp examination.

NEUROTROPHIC KERATITIS:

New Approaches to Manage Disease and Improve Patient Satisfaction

Release Date: May 1, 2020
CME Expiration May 31, 2021
COPE Expiration Date: April 20, 2023

INSTRUCTIONS FOR CME CREDIT

To receive credit, you must complete the attached Post Test/Activity Evaluation/Satisfaction Measures Form and mail or fax to Evolve Medical Education LLC; 353 West Lancaster Avenue, Second Floor, Wayne, PA 19087; Fax: (215) 933-3950. To answer these questions online and receive real-time results, please click <https://evolvemeded.com/online-courses/1935-supplement>. If you are experiencing problems with the online test, please email us at info@evolvemeded.com. Certificates are issued electronically; please be certain to provide your email address below.

Please type or print clearly, or we will be unable to issue your certificate.

Full Name _____ ☐ MD/DO participant ☐ OD ☐ non-MD participant

Phone (required) _____ ☐ Email (required) _____

Address/P.O. Box _____

City _____ State/Country _____ Zip/Postal Code _____

License Number _____ OE Tracker Number _____

DEMOGRAPHIC INFORMATION

Profession	Years in Practice	Patients Seen Per Week (with the disease targeted in this activity)	Region	Setting	Models of Care
<input type="checkbox"/> MD/DO	<input type="checkbox"/> >20	<input type="checkbox"/> 0	<input type="checkbox"/> Northeast	<input type="checkbox"/> Solo Practice	<input type="checkbox"/> Fee for Service
<input type="checkbox"/> OD	<input type="checkbox"/> 11-20	<input type="checkbox"/> 1-15	<input type="checkbox"/> Northwest	<input type="checkbox"/> Community Hospital	<input type="checkbox"/> ACO
<input type="checkbox"/> NP	<input type="checkbox"/> 6-10	<input type="checkbox"/> 16-30	<input type="checkbox"/> Midwest	<input type="checkbox"/> Government or VA	<input type="checkbox"/> Patient-Centered Medical Home
<input type="checkbox"/> Nurse/APN	<input type="checkbox"/> 1-5	<input type="checkbox"/> 31-50	<input type="checkbox"/> Southeast	<input type="checkbox"/> Group Practice	<input type="checkbox"/> Capitation
<input type="checkbox"/> PA	<input type="checkbox"/> <1	<input type="checkbox"/> 51+	<input type="checkbox"/> Southwest	<input type="checkbox"/> Other	<input type="checkbox"/> Bundled Payments
<input type="checkbox"/> Other				<input type="checkbox"/> I do not actively practice	<input type="checkbox"/> Other

LEARNING OBJECTIVES

DID THE PROGRAM MEET THE FOLLOWING EDUCATIONAL OBJECTIVES?

AGREE NEUTRAL DISAGREE

Describe the stages of neurotrophic keratitis, and how to differentiate it from similar diseases

Recognize the various potential causes of neurotrophic keratitis

Understand mechanisms of action of newer treatments and when they should be introduced into treatment regimens for neurotrophic keratitis

Identify the relationships between disease characteristics, drug, treatment frequency, visual and anatomic outcomes

POSTTEST QUESTIONS

1. Based on this activity, please rate your confidence in your ability to diagnose neurotrophic keratitis.
 - a. Not at all confident
 - b. Not very confident
 - c. Neutral
 - d. Confident
 - e. Very confident
2. Corneal sensitivity testing is a key step in diagnosing neurotrophic keratitis. Of the following, all are qualitative tests, NOT quantitative, EXCEPT:
 - a. Cotton wisp
 - b. Tip of a tissue
 - c. Cochet-Bonnet esthesiometer
 - d. Unwaxed dental floss
3. Which of the following are risk factors for a 75-year-old man with a previous history of "corneal abrasion"?
 - a. History of Herpes zoster
 - b. History of nonhealing epithelial defect
 - c. History of LASIK
 - d. All of the above
4. What are some therapeutic options for nonhealing epithelial defect after corneal transplant?
 - a. Bandage contact lens
 - b. Tarsorrhaphy
 - c. Serum drops
 - d. Cenergermin-bkbj
 - e. All of the above
5. What percent of patients remained healed 1 year (48 weeks) after cessation of treatment in the REPARO trial?
 - a. 10%
 - b. 50%
 - c. 80%
 - d. 100%
6. In clinical trials of cenergermin 20 mcg/mL on neurotrophic keratitis patients, how many of the up to 72% that healed were still healed a year later (48 weeks) without any additional therapy?
 - a. 10%
 - b. 25%
 - c. 50%
 - d. 80%
7. A 78-year-old woman with a history of diabetic neuropathy and proliferative diabetic retinopathy is referred following a pars plana vitrectomy with irregular whorling epithelium causing decreased vision. Her referring eye care specialist has tried preservative-free artificial tears hourly, escalated to gels and ointments as well as topical lifitegrast then topical cyclosporine, and recently tried a self-retaining amniotic membrane without much change in the clinical appearance. It's been a couple months and although there isn't an epithelial defect, the patient is getting frustrated at the lack of vision, but otherwise is in little discomfort. The appropriate next step should be the following:
 - a. Testing for corneal sensitivity
 - b. Temporary lateral tarsorraphy
 - c. Placing a bandage contact lens
 - d. Gunderson style conjunctival flap
 - e. Culture to rule out infection
8. Which topical treatment for neurotrophic keratitis is structurally identical to the nerve growth factor protein?
 - a. Corticosteroids
 - b. Autologous serum eyedrops
 - c. Antibiotics
 - d. Cenergermin-bkbj
9. In the United States, neurotrophic keratitis affects how many people?
 - a. Fewer than 65,000
 - b. More than 65,000
 - c. There are no published estimates of disease prevalence
10. What is the most common ocular cause of neurotrophic keratitis?
 - a. Ocular surgery
 - b. Herpetic infections
 - c. Laser vision correction
 - d. Contact lens wear
11. The stepwise approach developed by Sacchetti and Lambiase is commonly used to treat patients with neurotrophic keratitis. Which of the following describes the first step?
 - a. Stage the disease and treat any associated ocular surface disease or comorbidities
 - b. Perform a direct corneal neurotization procedure
 - c. Perform a confirmatory corneal sensitivity test

CRST

Cataract & Refractive Surgery Today

MODERNOPTOMETRY

