

CRST

Cataract & Refractive Surgery Today

TARGETING THE TRABECULAR MESHWORK:

The Cataract-Refractive
Perspective

Gagan Sawhney, MD

Blake Williamson, MD, MPH, MS

This activity is supported by an unrestricted educational grant from New World Medical.

This activity is provided by Evolve Medical Education.

Provided by


evolve
medical education

Targeting the Trabecular Meshwork: The Cataract-Refractive Perspective

Release Date: June 2020

Expiration date: July 2021

FACULTY



GAGAN SAWHNEY, MD

Cataract, Glaucoma,
and Refractive Surgeon
Georgia Eye Partners
Atlanta, Georgia



BLAKE WILLIAMSON, MD, MPH, MS

Refractive, Cataract, and MIGS Surgeon
Williamson Eye Center
Baton Rouge, Louisiana

ACTIVITY DESCRIPTION

This supplement, part of a multipart curriculum titled *Targeting the Trabecular Meshwork: Goniotomy Past, Present, and Future*, focuses on the changing treatment of open-angle glaucoma. Trabeculectomy and tube-shunt surgery have for decades been the mainstay of surgical glaucoma therapy, but during the past decade, minimally invasive glaucoma surgeries (MIGS) have offered patients a safe alternative with trabeculectomy-like reductions in IOP. This content focuses on MIGS procedures that target the Schlemm canal.

TARGET AUDIENCE

This educational activity is intended for ophthalmologists involved in the treatment of glaucoma.

LEARNING OBJECTIVES

At the completion of this educational activity, the participating eye care provider will be better able to:

- **Identify** and **understand** the advantages and disadvantages of trabecular, supraciliary, and subconjunctival MIGS procedures.
- **Describe** the efficacy and safety of trabecular meshwork (TM) and Schlemm canal MIGS procedures.
- **Identify** the patient characteristics that favor the use of TM and Schlemm canal MIGS procedures.
- **Adopt** optimal surgical techniques when performing TM and Schlemm canal MIGS procedures.

GRANTOR STATEMENT

This activity is supported by an unrestricted educational grant from New World Medical.

ACCREDITATION STATEMENT

Evolve Medical Education LLC (Evolve) is accredited by the Accreditation Council for Continuing Medical Education (ACCME) to provide continuing medical education for physicians.

CREDIT DESIGNATION STATEMENT

Evolve designates this enduring material for a maximum of .5 AMA PRA Category 1 Credits™. Physicians should claim only the credit commensurate with the extent of their participation in the activity.

TO OBTAIN CREDIT

To obtain credit for this activity, you must read the activity in its entirety and complete the Posttest/Activity Evaluation/Satisfaction Measures Form found online, which consists of a series of multiple-choice questions. To answer these questions online and receive real-time results, please visit <https://evolvemeded.com/online-courses/1928-supplement-2>. Upon completing the activity and self-assessment test, you may print a CME Credit letter.

DISCLOSURE POLICY

It is the policy of Evolve that faculty and other individuals who are in the position to control the content of this activity disclose any real or apparent conflicts of interests relating to the topics of this educational activity. Evolve has full policies in place that will identify and resolve all conflicts of interest prior to this educational activity.

The following faculty/staff members have the following financial relationships with commercial interests:

Gagan Sawhney, MD, and/or spouse, has had a financial agreement or affiliation during the past year with the following commercial interests in the form of *Speaker's Bureau*: Aerie Pharmaceuticals, Allergan, and New World Medical.

Blake Williamson, MD, MPH, MS, and/or spouse, has had a financial agreement or affiliation during the past year with the following commercial interests in the form of *Consultant and Speaker's Bureau*: New World Medical.

EDITORIAL SUPPORT DISCLOSURES

The Evolve staff and planners have no financial relationships with commercial interests. Nisha Mukherjee, MD, peer reviewer, has no financial relationships with commercial interests.

DISCLAIMER

The views and opinions expressed in this educational activity are those of the faculty and do not necessarily represent the views of Evolve, *Cataract & Refractive Surgery Today*, or New World Medical.

To view the online version of this supplement and to receive credit, please visit <https://evolvemeded.com/online-courses/1928-supplement-2>.

PRETEST QUESTIONS

Please complete prior to accessing the material and submit with the Posttest/Activity Evaluation/Satisfaction Measures found online at: <https://evolvemed.com/online-courses/1928-supplement-2>.

- 1. Please rate your confidence in your understanding of microinvasive glaucoma surgery (MIGS) procedures (based on a scale of 1 to 5, with 1 being not at all confident and 5 being extremely confident).**
 - a. 1
 - b. 2
 - c. 3
 - d. 4
 - e. 5
- 2. Please rate how often you intend to apply advances in the management of glaucoma in the clinic (based on a scale of 1 to 5, with 1 being never and 5 being always).**
 - a. 1
 - b. 2
 - c. 3
 - d. 4
 - e. 5
- 3. All but which one is a contraindication for goniotomy with trabecular meshwork (TM) excision?**
 - a. Uveitis
 - b. Goal IOP >10 mm Hg
 - c. Neovascularization of the iris
 - d. Neovascularization of the angle
- 4. Which MIGS device is only approved to be performed with cataract surgery?**
 - a. Glaukos iStent
 - b. Santen MicroShunt
 - c. NeoMedix Trabectome
 - d. Allergan XEN Gel Stent
- 5. Following a MIGS procedure, patients should be advised they may have blurred vision for how long (on average)?**
 - a. 1 to 2 hours
 - b. 1 to 2 days
 - c. 1 to 2 weeks
 - d. 1 to 2 months
- 6. Which of the following describes a patient best suited for a trabecular-based MIGS procedure?**
 - a. Mild to moderate disease
 - b. Able to tolerate some medications
 - c. IOP target of 15 to 18 mm Hg
 - d. All of the above
- 7. Which type of procedure requires a steeper learning curve than others?**
 - a. Supraciliary MIGS
 - b. Subconjunctival MIGS
 - c. TM/Schlemm Canal MIGS
 - d. All of the above
- 8. What is a differentiating factor between traditional and excisional goniotomy?**
 - a. Can be used to treat pediatric glaucoma.
 - b. Used to open an obstructed TM
 - c. Performed under direct gonioscopy to visualize area.
 - d. Elevates and excises TM to access multiple collector channels.

Targeting the Trabecular Meshwork: The Cataract-Refractive Perspective

This supplement summarizes a webinar available on the Evolve Medical Education website. Click the link to view the full-length webinar featuring two anterior segment experts discussing excisional goniotomy for the cataract-refractive surgeon, including surgical pearls, case studies, and tackling audience questions. <https://evolvemeded.com/course-group/targeting-the-trabecular-meshwork-goniotomy/>.

We are living in a glaucoma renaissance. It's important for us to focus on minimally invasive glaucoma surgeries (MIGS) and understand the different options that are available, because glaucoma is the second leading cause of blindness worldwide¹ and often goes undiagnosed.^{2,3}

Glaucoma is only young once. If we do not diagnose and treat it early in the disease course, we can't reverse the damage. With traditional glaucoma drops, ideal intraocular pressures (IOPs) are often not achieved, mostly because of compliance issues. Reasons for noncompliance can range from difficulty administering drops, lack of access, cost, or intolerable side effects. By not offering MIGS to these patients earlier in the disease course, we are doing them a disservice.

It has been estimated that 20 to 30% of patients undergoing cataract surgery have some component of ocular hypertension or glaucoma.⁴ Performed with cataract surgery or without, MIGS can help improve compliance, help prevent glaucomatous optic neuropathy, help prevent the need for more invasive glaucoma surgical procedures.^{5,6}

There are a variety of MIGS options and the same MIGS is not a good choice for every single patient. You need multiple tools in your toolbox to find the best option for each patient, and it's wise to master one MIGS before moving to the next. It's also important to understand that a comprehensive ophthalmologist may choose a different MIGS procedure than a glaucoma specialist.

—Gagan Sawhney, MD; and Blake Williamson, MD, MPH, MS

1. World Health Organization. Glaucoma is second leading cause of blindness globally. *Bull World Health Organ.* 2004;82:811-890.
2. Swanson MW. Undiagnosed and overdiagnosed glaucoma in the United States. *Invest Ophthalmol Vis Sci.* 2012; 53:6379.
3. Glaucoma Research Foundation. Glaucoma Facts and Stats. www.glaucoma.org/glaucoma/glaucoma-facts-and-stats.php. Accessed January 9, 2020.
4. Shrivastava A, Friedman D, Singh K, et al. Prevalence of glaucoma in a cataract surgery population. Presented at: 2016 American

Society for Cataract and Refractive Surgery Symposium; May 6-10; New Orleans.
5. Sharif NA. Glaucomatous optic neuropathy treatment options: the promise of novel therapeutics, techniques and tools to help preserve vision. *Neural Regen Res.* 2018;13(7):1145-1150.
6. Fingeret M, Dickerson JE Jr. The role of minimally invasive glaucoma surgery devices in the management of glaucoma [published correction appears in *Optom Vis Sci.* 2018 Jun;95(6):554]. *Optom Vis Sci.* 2018;95(2):155-162.

SAFETY FIRST: A REVIEW OF CONVENTIONAL PATHWAY MIGS OPTIONS

BY BLAKE WILLIAMSON, MD, MPH, MS

As a high-volume refractive cataract surgeon, in my practice I treat more mild-to-moderate glaucoma. Safety is my primary goal in terms of what I want out of my MIGS procedures, and I want to make sure it doesn't change my refractive outcomes. But I also believe compliance is important.

I believe if a patient's glaucoma continues to progress, despite being on two drops, that we are not properly caring for that patient by offering him or her a third drop. This patient should be considered for a MIGS procedure. Many of my patients are just as happy to eliminate drops as they are to stop wearing bifocals after I implant a toric IOL, for example.

MIGS procedures are classified based on their outflow pathway. The trabecular meshwork (TM)/Schlemm canal is the conventional outflow pathway, followed by supraciliary and then the

scleral/subconjunctival pathways. The conventional outflow pathway has been most commonly used by the comprehensive cataract surgeon or refractive surgeon because of the safety profile.¹

I believe most glaucoma surgeons are still excited about the supraciliary and subconjunctival spaces and the procedures that target those areas. The first ab interno supraciliary microstent (Alcon) to receive FDA approval in 2017 is no longer available, but a supraciliary microstent from Glaukos is expected to gain FDA approval later this year. Another supraciliary device, a biocompatible silicon containing a geometric porous microstructure (iStar Medical), is also under investigation. Available devices for the subconjunctival space include the gel stent from Allergan and a filtration device from Alcon. A microshunt from Santen is also expected to receive FDA approval later this year.

REVIEW OF DEVICES

Since the release of the first MIGS device in 2012, there has been a MIGS explosion. This review focuses on the conventional pathway.

Glaukos iStent Inject — An ab interno glaucoma implant from Glaukos was approved by the FDA in 2012. Since that time, the manufacturer has released a second-generation implant indicated for use in conjunction with cataract surgery (Figure 1). Two multidirectional stents are placed 2 to 3 clock hours apart.² I've had terrific results with both the first- and second-generation Glaukos stents.

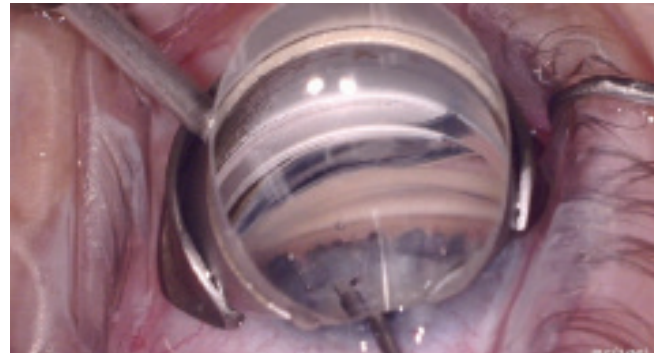
Sight Sciences Omni Glaucoma Treatment System — This device combines ab interno trabeculotomy and canaloplasty into one using a single device (Figure 2). There is a microcatheter threaded through a cannula designed to be used through the cataract surgery incision.³ What I find to be most unique about this procedure is that it combines both canaloplasty with the ability to thereafter strip the TM times 360 degrees. I find it to be especially beneficial for patients with more severe glaucoma. This can be done in conjunction with cataract surgery or as a standalone procedure.

Ivantis Hydrus Microstent — My practice was one of the first in Louisiana to begin implanting this microstent. It's an intracanalicular scaffold that bypasses the TM and expands Schlemm canal. It can only be implanted at the time of cataract surgery in patients with mild to moderate primary open-angle glaucoma (Figure 3).⁴

NeoMedix Trabectome — This is an electro-surgical ab interno procedure using a handheld device. The second generation of this device allows for the removal of the TM with a serrated, ramping, diverging two-blade device. A console is not needed, and it can also be used with irrigation and aspiration from any device, such as a phacoemulsification machine (Figure 4). This surgery can be performed as a standalone procedure, but it is more commonly combined with cataract surgery.^{5,6}

New World Medical Kahook Dual Blade — This was the very first MIGS procedure I performed when I started in private practice. I liked the idea of a procedure that could be versatile with a good efficacy and safety profile (Figure 5). I like to say that MIGS is about buying time and saving real estate: buying time before the next glaucoma procedure and doing the least invasive intervention to allow for potential future procedures. A goniotomy with the dual blade can be performed as a standalone or combined with cataract surgery.⁷

WATCH IT NOW



To see Drs. Sawhney and Williamson discuss excisional goniotomy and share surgical videos and pearls, follow the link to the webinar (worth 1.5 CME credits): <https://evolvemed.com/course-group/targeting-the-trabecular-meshwork-goniotomy/>.

MY EXPERIENCE PLUS THE LITERATURE

I like to use the dual blade as both a standalone procedure and in conjunction with cataract surgery. Results of a study in which I participated show how the dual blade procedure combined with phacoemulsification results in lower IOP than phaco combined with the Glaukos stent.⁸ This study was conducted because many surgeons were familiar with using the first-generation Glaukos stent and the dual blade from New World Medical was still new to the MIGS space. There was interest in the ophthalmic community in comparing the two procedures.

We looked at patients through 12 months who had a percentage of greater than or equal to 20% IOP reduction at 1 year. We found that 64% of patients who underwent phaco with goniotomy had a reduction of at least 20% at 1 year, versus only 41% in the phaco with stent group.

You need a patient with a good view of the angle. Having a well pigmented TM can help with your first few cases. If you have TM that is very faintly pigmented, you can stain it with TM to enhance visualization. The key to any MIGS procedure is to get a good view of the iridocorneal angle.

I like to use the dual blade on many of my glaucoma patients, but there are some contraindications,⁹ like with any of the MIGS

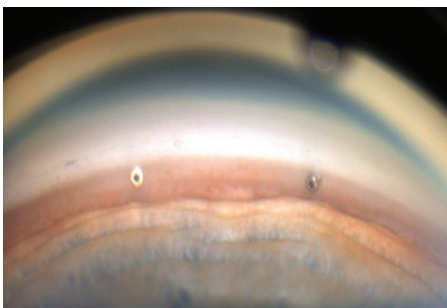


Figure 1. Two multidirectional stents are placed 2 to 3 clock hours apart.

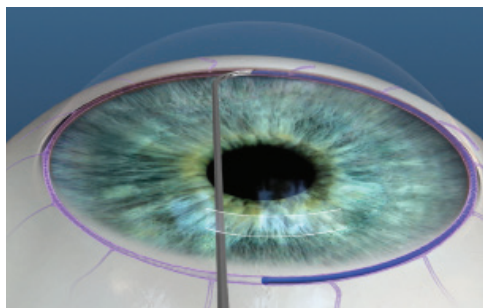


Figure 2. This device performs ab interno trabeculotomy and canaloplasty.

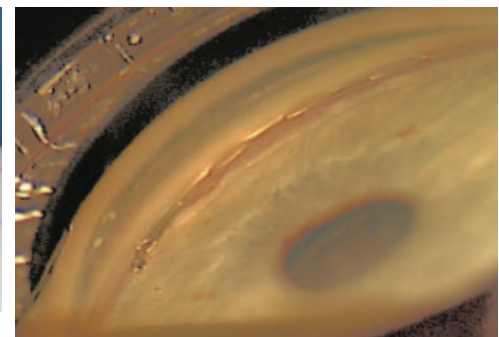


Figure 3. The microstent is an intracanalicular scaffold.

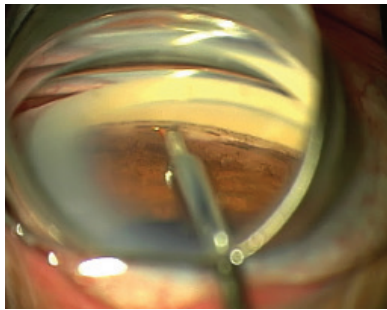


Figure 4. This device performs goniotomy via an electrocautery approach.

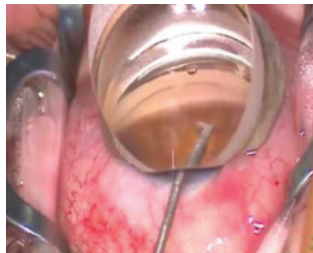

Figure 5. Dual blade goniotomy. The blade is designed in such a way that it excises instead of incises and does this without damage to the adjacent tissue.

procedures. I would not perform a dual-blade goniotomy on a patient who has active neovascular glaucoma, active uveitic glaucoma, or anyone with elevated EVP because of the potential for reflux bleeding. If you cannot view the angle, you're not going to be able to place the dual blade there. I also would not perform

a dual-blade goniotomy in a patient who needs a dramatic drop in pressure.

In conclusion, I would like to make two requests to the ophthalmic surgeons reading this. First is not to ignore glaucoma at the time of cataract surgery and the second is to consider intervening with the dual blade procedure as a standalone, which you can use in a patient who has already had cataract surgery.

1. Kent C. MIGS and the general ophthalmologist. *Review of Ophthalmology*. reviewofophthalmology.com/article/migs-procedures-and-the-general-ophthalmologist. Updated June 10, 2019. Accessed May 15, 2020.
2. iStent inject. Glaukos. Directions for Use. glaukos.com/wp-content/uploads/2017/09/45-0176-Rev-1-Artwork-IFU-G2-M-IS-Commercial-US-1.pdf. Updated June 2018. Accessed May 28, 2020.
3. OMNI. Sight Sciences. Important safety information. <https://omnisurgical.com>. Accessed May 28, 2020.
4. Hydrus Microstent Instructions for Use. Updated August 2018. accessdata.fda.gov/cdrh_docs/pdf17/P170034D.pdf. Updated August 2018. Accessed May 28, 2020.
5. NeoMedix Trabectome. <https://www.neomedix.net/Technology/SurgicalSteps>. Accessed May 28, 2020.
6. *Current Developments in Glaucoma Surgery and MIGS*, edited by JR Samples, IJK Ahmed. Vol 1:245-248. Kugler Publications. 2020. Amsterdam, The Netherlands.
7. Kahook Dual Blade. New World Medical. Instructions for use. [newworldmedical.com/wp-content/uploads/2019/12/KDB-IFU-50-0069.pdf](https://www.newworldmedical.com/wp-content/uploads/2019/12/KDB-IFU-50-0069.pdf). Accessed May 28, 2020.
8. Lee D, King J, Thomsen S, et al. Comparison of surgical outcomes between excisional goniotomy using the Kahook Dual Blade and iStent trabecular micro-bypass stent in combination with phacoemulsification. *Clin Ophthalmol*. 2019;13:2097-2102.
9. Dorairaj SK, Kahook MY, Williamson BK, et al. A multicenter retrospective comparison of goniotomy versus trabecular bypass device implantation in glaucoma patients undergoing cataract extraction. *Clin Ophthalmol*. 2018;12:791-797.

CASE STUDY

by Blake Williamson, MD, MPH, MS

A 71-year-old female presented with a history of primary open-angle glaucoma. She previously underwent phacoemulsification plus implantation of a Glaukos stent in her right eye. She also had persistent cystoid macular edema that resolved, but it resulted in an IOP spike of about 50 mm Hg. We treated her with the maximum number of topical and oral medications, including netarsudil 0.02% and acetazolamide, and her IOP reduced to 30 mm Hg.

This case is interesting because 4 to 5 years ago, this patient would have automatically had a trabeculectomy or tube shunt surgery, but now we have options. I believe I had two options for this patient: a gel

stent or a dual-blade goniotomy. I chose the dual-blade goniotomy because you can excise the TM on either side of the stent already placed.

Before the removal of the Alcon microstent from the market, I often performed a dual-blade goniotomy after implantation of the microstent. I liked doing that and removing more of the TM if possible, because if it doesn't give me the efficacy I want, I could go back and implant the gel stent.

The dual-blade goniotomy worked very well in this patient and her IOP dropped to 14 mm Hg and stabilized there. She remains on a single combination drop.

EVIDENCE FOR THE EFFECTIVENESS OF MIGS PLUS CATARACT SURGERY

BY GAGAN SAWHNEY, MD

I am a glaucoma physician, but I perform a lot of cataract and glaucoma surgeries. Many of my patients who are undergoing cataract surgery have early glaucoma. For those patients, we discuss the pros and cons of adding a MIGS procedure—a discussion I believe every cataract surgeon and every glaucoma surgeon should have with every patient when they're thinking about moving forward with surgery.

The goal of goniotomy is focus on that conventional pathway. The highest resistance to outflow is the trabecular meshwork (TM), and we want to bypass the TM, get into Schlemm canal and access those collector channels to enhance aqueous outflow. It

can be difficult to identify where exactly the collector channel is located because when you're looking at the angle with a gonioscopic view in the operating room, typically you're seeing pigmented TM and you're not really seeing Schlemm canal or the collector channels behind it.

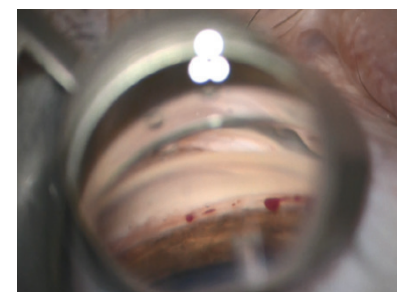

Figure 1. This image shows every single blood signal is blood dumped from the episcleral venous system through the collector channels into the anterior chamber.

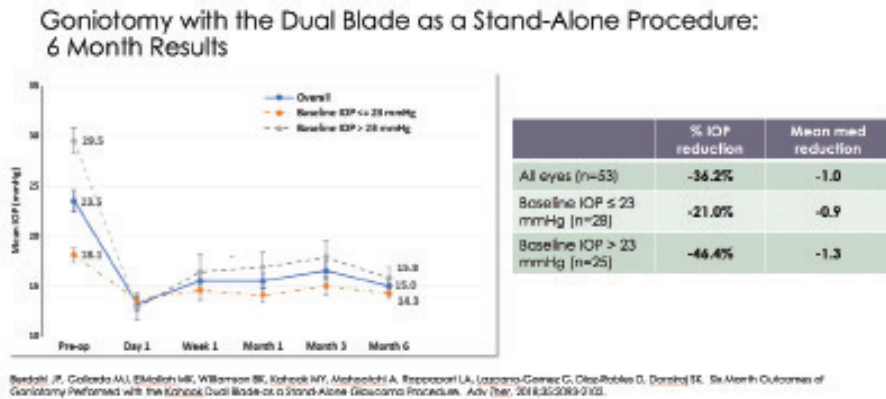


Figure 2. At the 6-month mark, mean IOP reduced to about 15 mm Hg.

Prospective Long-Term Efficacy Outcomes of Combined Cataract Surgery and Excisional Goniotomy with the Dual Blade

Objective	To describe the long-term IOP and medication use outcomes following this procedure in eyes with glaucoma
Methods	Prospective, multi-center interventional case series. Long-term outcomes from a subset of subjects of a single center are reported here.
Primary Outcomes	<ul style="list-style-type: none"> Proportion of patients maintaining ≥ 20% IOP reduction at last follow-up. Proportion of patients on ≥ 1 fewer medication at last follow-up.
Secondary Outcome(s)	Mean IOP change from baseline at last follow-up.
Subjects	<p>24 subjects followed for a mean of 29.3 months (range 22-35 months)</p> <p>67% POAG, 25% Angle Closure, 8% Pigmentary</p> <p>40% Mild, 24% Moderate, 36% Severe Glaucoma</p>

ElMallouk MK, Salehd JJ, Kahook MY, et al. 12-month retrospective comparison of Kahook Dual Blade excisional goniotomy with trabeculectomy in glaucoma eyes at the time of cataract surgery. Adv Ther. 2019;34(1):20-27.

Figure 3. There was a 31% reduction in mean IOP from baseline to the last follow-up at 29 months.

There is a MIGS procedure I use that helps me access multiple collector channels: dual-blade goniotomy. A single sweep with the dual blade enables me to access multiple collector channels (Figure 1). The more collector channels you expose, the better the postoperative results. I have found the dual-blade goniotomy to be both safe and efficacious and there is now a growing body of evidence to support my clinical experience.

THE LITERATURE

Since 2017, there have been 10 new peer-reviewed studies about the dual-blade goniotomy, and more are on the way. These studies show the versatility of the dual-blade goniotomy because the studies have been done in combination with cataract surgery and as a standalone procedure and the patients include severe refractory glaucoma patients, and angle closure glaucoma patients.¹⁻¹²

Overall, these studies are through 6 and 12 months of follow-up, and median outcomes include an IOP reduction of 4.4 mm Hg, an endpoint IOP of 13.7 mm Hg, and a reduction in at least one medication.

I would like to highlight two studies in particular. The first study, a retrospective, multicenter, interventional case series led by John P. Berdahl, MD, was designed to characterize the reduction in IOP

and IOP-lowering medication use following excisional goniotomy using dual-blade goniotomy as a stand-alone procedure in adult eyes with glaucoma uncontrolled on a regimen of topical IOP-lowering medications.¹¹ The study included both phakic and pseudophakic patients, and preoperative, operative, and postoperative data was collected through 6 months.

The study results showed the mean baseline IOP was about 23.5 mm Hg (Figure 2). At the 6-month mark, mean IOP reduced to about 15 mm Hg. Looking specifically at patients who had a higher baseline IOP, 23 mm Hg and higher, those patients had a greater percent drop in IOP, from 29.5 to about 15.8 mm Hg. Higher starting pressures allowed for greater absolute value drop in IOP.¹¹

The dual-blade goniotomy is also effective with lower starting pressures. Patients with starting pressures of 18.1 mm Hg at the 6-month follow-up had an IOP of about 14 mm Hg. This study shows an IOP reduction in both phakic and pseudophakic patients, and a reduction in medications.¹¹ Although it's not yet published, I have seen additional data and that effect remains through year 3 (unpublished data).

In my own personal experience, I'm typically able to remove one or two glaucoma medications from most patients' regimens, sometimes even more.

The second study I want to highlight is a prospective, multicenter interventional case series led by Syril Dorairaj, MBBS, MD. The study was designed to characterize the reduction in IOP and IOP-lowering medication use following excisional dual-blade goniotomy as a stand-alone procedure in adult eyes with glaucoma uncontrolled on a regimen of topical IOP-lowering medications.⁶

The primary outcome was the proportion of patients maintaining at least a 20% IOP reduction and also the proportion of patients on at least one fewer medication at the last follow-up. The study included 26 patients with primary open-angle glaucoma, angle closure, and pigmentary glaucoma, ranging from mild to moderate to severe, and patients were followed for a mean of about 29 months. There was a 31% reduction in mean IOP from baseline to the last follow-up at 29 months. Patients were using about 1.8 drops at baseline and dropped to 0.5 drops at the end of 29 months, a 72% reduction in IOP lowering medications in 85% of patients who were on at least one medication (Figure 3).⁶

This is terrific efficacy in terms of IOP reduction and great for lifestyle in terms of medication burden. This study is particularly important because it reflects what we see in our practices.⁶

1. Greenwood MD, Seibold LK, Radcliffe NM, et al. Goniotomy with a single-use dual blade: Short-term results. *J Cataract Refract Surg.* 2017;43(9):1197-1201.
2. Dorairaj SK, Seibold LK, Radcliffe NM, et al. 12-month outcomes of goniotomy performed Using the Kahook Dual Blade combined with cataract surgery in eyes with medically treated glaucoma. *Adv Ther.* 2018;35:1460-1469.
3. Sieck EG, Epstein RS, Kennedy JB, et al. Outcomes of Kahook Dual Blade goniotomy with and without phacoemulsification cataract extraction. *Ophthalmology Glaucoma.* 2018;1(1):75-81.
4. Kormmann HL, Fellman RL, Feuer WJ, et al. Early results of goniotomy with the Kahook Dual Blade, a novel device for the treatment of glaucoma. *Clinical Ophthalmology.* 2019; 13:2369-2376.
5. Dorairaj SK, Kahook MY, Williamson BK, et al. A multicenter retrospective comparison of goniotomy versus trabecular bypass device implantation in glaucoma patients undergoing cataract extraction. *Clin Ophthalmol.* 2018;12:791-797.
6. ElMallah MK, Seibold LK, Kahook MY, et al. 12-month retrospective comparison of Kahook Dual Blade excisional goniotomy with iStent trabecular bypass device implantation in glaucomatous eyes at the time of cataract surgery. *Adv Ther.* 2019;36:515-2527.
7. Lee D, King J, Thomsen S, et al. comparison of surgical outcomes between excisional goniotomy using the Kahook Dual Blade and iStent trabecular micro-bypass stent in combination with phacoemulsification. *Clinical Ophthalmology.* 2019;13:2097-2102.
8. Hirabayashi MT King JT, Lee D, et al. Outcome of phacoemulsification combined with excisional goniotomy using the Kahook Dual Blade in severe glaucoma patients at 6 months. *Clin Ophthalmol.* 2019; 13:715-721.
9. Dorairaj S, Tam MD. Kahook Dual Blade excisional goniotomy and goniosynechialysis combined with phacoemulsification for angle-closure glaucoma: 6-month results. *J Glaucoma.* 2019;28(7):643-646.
10. Dorairaj S, Tam MD, Balasubramani GK. Twelve-month outcomes of excisional goniotomy using the Kahook Dual Blade in eyes with angle-closure glaucoma. *Clin Ophthalmol.* 2019,13:1779-1785.
11. Berdahl JP, Gallardo MJ, ElMallah MK, et al. Six-month outcomes of goniotomy performed with the Kahook Dual Blade as a stand-alone glaucoma procedure. *Adv Ther.* 2018;35(11):2093-2102.
12. Salinas L, Chaudhary A, Berdahl JP, et al. Goniotomy using the Kahook Dual Blade in severe and refractory glaucoma: 6-month outcomes. *J Glaucoma.* 2018;27(10):849-855.

DUAL-BLADE GONIOTOMY: PRE- AND POSTOPERATIVE PROTOCOLS

BY GAGAN SAWHNEY, MD; AND BLAKE WILLIAMSON, MD, MPH, MS

Informing patients ahead of time what to expect following their MIGS procedure is very important. When combining cataract surgery and a MIGS procedure, patients should be informed they will have outcomes that may differ from their friends who have had only cataract surgery. Patients should be told it is not unusual to have some bleeding that may limit their vision, and that by week 1 following surgery, their vision will return to normal.¹⁻⁴

From a surgical standpoint, it's vital to perform preoperative gonioscopy to view the corneal angle prior to surgery to know the orientation of the iris and the level of trabecular meshwork (TM) pigmentation. Sometimes the TM is so deeply pigmented that it can be difficult to identify. You must know where it is to be sure you're excising TM and not the dark ciliary body band.⁵ Patients can develop a ciliary body cleft from excising the wrong tissue.⁶ Therefore, it's important to be comfortable with gonioscopy. Studies have shown as many as 50% of ophthalmologists don't perform gonioscopy,⁷ either because they don't feel comfortable or they just don't know how. Surgical gonioscopy is a very different skillset than clinical split lamp gonioscopy and it's vital to practice.

Postoperatively, it is unnecessary to change the regimen when performing a dual-blade goniotomy plus phacoemulsification versus just phaco. The medication regimen typically includes steroids, antibiotics, and nonsteroidals. However, some surgeons may choose to include pilocarpine 1% twice a day for a month postoperatively to keep the iris constricted away from that cleft created by the goniotomy.⁸

The patient should also stop taking glaucoma drops during steroid/antibiotic/pilocarpine therapy.⁹ If their IOP is less than 12 mm Hg at day 1 following surgery, the patient does not need to instill their glaucoma drops. If their IOP is 12 to 15 mm Hg, they should instill one drop, and if it's higher than 15 mm Hg, the next step is dependent upon physician preference.¹⁰ Ideally, the patient should not be instilling drops by 1 month postoperative if they had mild to moderate glaucoma. A more severe glaucoma patient may need to remain on one to two drops following a MIGS procedure.¹¹ ■

1. Greenwood MD, Seibold LK, Radcliffe NM, et al. Goniotomy with a single-use dual blade: Short-term results. *J Cataract Refract Surg.* 2017;43(9):1197-1201.
2. Dorairaj SK, Seibold LK, Radcliffe NM, et al. 12-month outcomes of goniotomy performed using the Kahook Dual Blade combined with cataract surgery in eyes with medically treated glaucoma. *Adv Ther.* 2018;35:1460-1469.
3. Sieck EG, Epstein RS, Kennedy JB, et al. Outcomes of Kahook Dual Blade goniotomy with and without phacoemulsification cataract extraction. *Ophthalmology Glaucoma.* 2018;1(1):75-81.
4. Salinas L, Chaudhary A, Berdahl JP, et al. Goniotomy using the Kahook Dual Blade in severe and refractory glaucoma: 6-month outcomes. *J Glaucoma.* 2018;27(10):849-855.
5. Abu-Hassan DW, Acott TS, Kelley MJ. The trabecular meshwork: A basic review of form and function. *J Ocul Biol.* 2014;2(1).]
6. Ioannidis AS, Bunce C, Barton K. The evaluation and surgical management of cyclodialysis clefts that have failed to respond to conservative management. *Br J Ophthalmol.* 2014;98(4):544-549.
7. Fremont AM, Paul P, Lee PP, Mangione CM. Patterns of care for open-angle glaucoma in managed care. *Arch Ophthalmol.* 2003;121(6):777-783.
8. Beck AD, Lynn MJ, Crandall J, et al. Surgical outcomes with 360-degree suture trabeculotomy in poor-prognosis primary congenital glaucoma and glaucoma associated with congenital anomalies or cataract surgery. *J AAPOS.* 2011;15(1):54-58.
9. Vaajanen A, Vapaatalo H. A single drop in the eye - effects on the whole body? *Open Ophthalmol J.* 2017;11:305-314.
10. Fingeret M, Dickerson JE Jr. The role of minimally invasive glaucoma surgery devices in the management of glaucoma [published correction appears in *Optom Vis Sci.* 2018;95(6):554]. *Optom Vis Sci.* 2018;95(2):155-162.
11. Bloom P, Au L. "Minimally Invasive Glaucoma Surgery (MIGS) Is a Poor Substitute for Trabeculectomy"-The Great Debate. *Ophthalmol Ther.* 2018;7(2):203-210.