

Supplement to

July/August 2017

Modern Aesthetics®

CME Activity

Beyond Face Value

Sachin
Shridharani, MD

Sabrina Guillen
Fabi, MD

Jason D.
Bloom, MD

Steve
Yoelin, MD

A CME activity provided by Evolve Medical Education LLC
and distributed by *Modern Aesthetics®*

Supported by an unrestricted educational grant from Allergan plc.


evolve
medical education

Beyond Face Value

FACULTY



Sachin Shridharani, MD, Moderator

Board Certified Plastic Surgeon
LUXURGERY
New York, NY



Sabrina Guillen Fabi, MD

Dermatologist | Voluntary Assistant Clinical Professor in Medicine/Dermatology, University of California | Associate & Associate Research Director, Cosmetic Laser Dermatology San Diego, CA



Jason D. Bloom, MD

Facial Plastic Surgeon
Main Line Center for Laser Surgery
Ardmore, PA



Steve Yoelin, MD

Board Certified Ophthalmologist
Private Practice
Newport Beach, CA

CONTENT SOURCE

This continuing medical education (CME) activity captures content from a roundtable discussion held April 2017.

ACTIVITY DESCRIPTION

Office-based cosmetic surgical procedures are safe and cost-effective. Data show that they are popular among consumers. According to the 2015 American Society for Aesthetic Plastic Surgery (ASAPS) Annual Survey, Americans underwent nearly 8.9 million non-surgical cosmetic procedures performed by plastic surgeons, facial plastic surgeons, and cosmetic dermatologists. Of these, there were 3.5 million botulinum toxin type A injections and approximately 1.7 million hyaluronic acid (HA) injections. Cosmetic injectables, therefore, accounted for the majority of all non-surgical procedures—outpacing device-based procedures.

Some observers have noted that, despite developments, training programs are based on a single objective finding without regard for

the context of the rest of the face or the psyche of the patient.

Aesthetic physicians require education on a holistic approach to facial rejuvenation, with consideration of patient desires and the effects of treatment on their psyche.

TARGET AUDIENCE

This certified CME activity is designed for dermatologists, cosmetic surgeons, and residents in these fields.

LEARNING OBJECTIVES

Upon completion of this activity, the participant should be able to:

- Describe the properties of different injectable fillers and explain how these properties provide different lifting/filling effects.
- Devise strategies for facial rejuvenation that employ the unique characteristics of different fillers to achieve complementary effects.
- Identify opportunities for combination strategies for rejuvenation that optimize aesthetic outcomes, patient convenience, cost, and satisfaction.
- Describe the potential effects of facial rejuvenation on the patient psyche and discuss possible impact on quality of life.
- Utilize strategies to elicit patient desires and deliver combination approaches to facial rejuvenation that meet patient objectives.

ACCREDITATION STATEMENT

Evolve Medical Education LLC is accredited by the ACCME to provide continuing medical education for physicians.

AMA CREDIT DESIGNATION STATEMENT

Evolve Medical Education LLC designates this enduring material for a maximum of 1 AMA PRA Category 1 Credit.™ Physicians should claim only the credit commensurate with the extent of their participation in the activity.

TO OBTAIN CME CREDIT

To obtain CME credit for this activity, you must read the activity in its entirety and complete the Post Test/Activity Evaluation Form, which consists of a series of multiple choice questions. To answer these questions online and receive real-time results, please visit evolvemeded.com and click on "Online Courses." Upon completing the activity and achieving a passing score of 75% on this self-assessment test, you may print out credit letter awarding credit.

Alternatively, please complete the Post Test/Activity Evaluation Forms and mail or fax to Evolve Medical Education LLC; PO Box 358, Pine Brook, NJ 07058; Fax (610) 771- 4443. The estimated time to complete this activity is 1 hour.

GRANTOR STATEMENT

This continuing medical education activity is supported through an unrestricted educational grant from Allergan plc.

DISCLOSURE POLICY STATEMENT

It is the policy of Evolve Medical Education LLC that faculty and other individuals who are in the position to control the content of this activity disclose any real or apparent conflict of interests relating to the topics of this educational activity. Evolve Medical Education LLC has full policies in place that will identify and resolve all conflicts of interest prior to this educational activity.

The following faculty members have the following financial relationships with commercial interests:

Jason D. Bloom, MD has had a financial agreement or affiliation during the past year with the following commercial interests in the form of Consultant/Advisory Board/Speaker's Bureau: Allergan plc; Alma Lasers; Galderma Laboratories L.P.; InMode; Merz Pharma; Pharmaceutical Project Solutions (PPSI); Sinclair Pharma; and ThermiGen, LLC. Grant/Research Support: Allergan plc, Galderma Laboratories L.P.; and ZELTIQ Aesthetics, Inc. Stock/Shareholder: Cearna Inc.

Sabrina Guillen Fabi, MD has had a financial agreement or affiliation during the past year with the following commercial interests in the form of Consultant/Advisory Board/Speaker's Bureau: Allergan plc; Galderma Laboratories L.P.; Merz Pharma; and Valeant Pharmaceuticals. Grant/Research Support: Allergan plc, Galderma Laboratories L.P.; Merz Pharma; and Revance Therapeutics Inc.

Sachin Shridharani, MD has had a financial agreement or affiliation during the past year with the following commercial interests in the form of Consultant/Advisory Board/Speaker's Bureau: Allergan plc; Galderma Laboratories L.P.; Merz Pharma; and Miramar, Inc. Grant/Research Support: Allergan plc.

Steve Yoelin, MD has had a financial agreement or affiliation during the past year with the following commercial interests in

the form of Consultant/Advisory Board/Speaker's Bureau: Allergan plc and Galderma Laboratories L.P. Grant/Research Support: Allergan plc.

EDITORIAL SUPPORT DISCLOSURES

Cheryl Cavanaugh, MS, Evolve Medical Education LLC; Anthony Rossi, MD, Peer Reviewer

OFF-LABEL STATEMENT

This educational activity may contain discussion of published and/or investigational uses of agents that are not indicated by FDA. The opinions expressed in the educational activity are those of the faculty. Please refer to the official prescribing information for each product for discussion of approved indications, contraindications, and warnings.

DISCLAIMER

The views and opinions expressed in this educational activity are those of the faculty and do not necessarily represent the views of Evolve Medical Education LLC and Allergan plc.

Distributed with: *Modern Aesthetics*®



Go to evolvemeded.com/online-courses/ to view the online version of this supplement.

Beyond Face Value

The way that aesthetic doctors address and treat the aging face has changed dramatically in recent years due to both a newfound understanding and appreciation of how the face ages as well as the advent of new tools, technologies, and techniques. During a roundtable discussion, four leading physicians from four different disciplines shared their insights on what has changed and what is now possible—without surgery.

UNDERSTANDING FACIAL AGING: A NEW APPRECIATION

Facial aging begins as early as the mid-to-late 20s in men and women in fairly standard ways, typically with volume loss and age-related changes around the eyes being the first noticeable signs. Next, individuals may see a drop in their cheeks, followed by a more pronounced hollowing underneath the eyes.

“Patients are particularly aware of changes around their eyes because most time spent looking at others is focused on their eyes,” said Steve Yoelin, MD, an ophthalmologist in Newport Beach, CA.

While the eyes do get the most attention, it should not be at the expense of the forehead, temples, mid-face changes at the bony level, zygoma or maxilla, and/or the lower third of the face (the mouth area). A comprehensive approach to and understanding of the aging face is the best way to create optimal outcomes for patients, the panelists agreed.

It’s also important to think about what’s happening below the skin. This area of attention is a marked reversal, as in the past aesthetic doctors concentrated on changes in the skin because all of the products affected the skin. Now, thanks to new tools and techniques, there is an appreciation of the changes to bone, muscle, and deep fat or superficial fat that occur in the upper third, the middle third, and the lower third of the face.

Facial aging is more than skin deep, agreed moderator Sachin Shridharani, MD, a board-certified plastic surgeon in New York, NY. “When I think about the characteristics of the aging face, it doesn’t have to be completely wrinkled and sagged to look aged,” he said. “Loss of volume in places we like it and, of course, volume accumulation in the places we don’t want also are hallmarks of the aging face.”

A youthful face is traditionally heart-shaped with most of the volume up in the cheek and mid-face area, and a slimming down toward the chin, said Jason D. Bloom, MD, a facial plastic surgeon at Main Line Center for Laser Surgery in Ardmore, PA. An aging face is the inverse. “You start to get more fullness along the jawline, in the jowl area, and you lose that fullness up in the cheek area. It’s the upside-down triangle of aging.”

While our understanding of the aging face has changed, the facial aesthetic ideal has remained the same. The iconic beauties



A helpful exercise for newer injectors or individuals who are thinking about becoming more involved with injectables is to divide the face into thirds starting at the top of the head (at the hairline), and working all the way down to the clavicles. This exercise serves to highlight all the different changes that occur with facial aging, and to identify the proper targets for intervention.

of the past—Elizabeth Taylor, Marilyn Monroe, Audrey Hepburn, Grace Kelly, and Brigitte Bardot, for example—are still considered quite remarkably beautiful today.

That said, what has changed and changed significantly is the

ability, without surgery, to create or recreate the proportions most associated with beauty and youth.

“Although patients unfortunately can’t go back in time with their appearance, we strive to improve their beauty and youthfulness as best we can through the use of non-invasive means,” Dr. Yoelin said.

Dr. Bloom agreed. “Even if we’re not truly changing the shape of the lower face, by putting some volume in the upper face, we can recreate that heart shape without a true transfer of tissue.”

When there was only collagen, aesthetic doctors just filled lines, the panelists noted. “And then, in the early 2000s, we started filling folds, and now, it’s less about that and more about literally shaping faces. We create beauty rather than just filling in lines,” Dr. Bloom said.

This same paradigm has been seen in facial aesthetic surgery. In the past, surgeons could only attempt to make a patient appear more youthful by pulling their skin and soft tissue envelope, tighter and tighter still. This approach led to a tighter version of an aged look, not a more youthful appearance.

But now surgeons can do much more, including adding volume back strategically to restore beauty for some patients and to create it anew in others. Some patients have never really had much visible vermilion show, and now it can be increased with the new hyaluronic acid (HA)-based fillers to create beauty.

A CHOICE OF RICHES

There are a multitude of HA-based fillers available today, with even more in the pipeline. (See Table 1) This is quite different from the early 2000s when there was just one flavor of HA filler with no lidocaine.

Even then, aesthetic doctors were thrilled, as HA lasts longer than collagen. “We initially only knew how to use the first available hyaluronic acid to fill depressions and augment lips,” Dr. Yoelin recalled. “Still, even these limited applications were a major advancement.”

As other fillers with different “personalities” emerged, surgeons went from painting in black and white to painting in different shades and different colors. Today’s fillers are robust enough to create structure. Now doctors, using needles or cannulas, can create structure in the face without having to take a patient to the operating room. “The range of application techniques and knowledge of the aging process have both come a long way in relatively short order, enabling practitioners to more effectively use the same hyaluronic acid dermal fillers,” Dr. Yoelin said.

There are more fillers available in Europe than in the United States, but those that are approved for use in the US have gone through rigorous testing and approval processes to assure their safety and effectiveness.

The more the merrier, the panelists agreed. “I’d be remiss to say that we could have done it all with just one single filler,” Dr. Yoelin said. “I need a collection of fillers in order to create the best results for my patients.”

One of the challenges is how to characterize these fillers, especially when introducing them to new injectors and/or filler-naïve patients. “I typically think of fillers in terms of robustness and

hydrophilicity, which determine depth and location of injection, respectively,” Dr. Yoelin said.

This terminology may be easier for a new injector to understand than G-prime, G double prime, cohesivity, flexibility, and other adjectives that are banded about.

Dr. Bloom agreed that expert injectors often know which HA filler is best for volume, which is a better lifter, and when combinations of multiple products are needed. These nuances may be lost on newer injectors, at least initially.

PATIENT EDUCATION

When it comes to patient education about the new crop of fillers, the key is an open conversation about aesthetic goals and expectations. “Patients come in. They say, ‘I want X.’ And I say, ‘How about I’ll do the best thing for you? And you’re going to get better results. And sometimes even pay less money,’” Dr. Bloom said.

“Not only do these fillers bring in different gel properties that allow us to treat all kinds of different anatomic changes as well as people who have thinner skin, or thicker skin, but also they come to market with new indications,” added Sabrina Guillen Fabi, MD, a dermatologist in San Diego. “The different gels and the different properties definitely help me customize my approach to each individual patient.”

With each new indication and approval, the companies that market fillers help aesthetic doctors educate the public. Direct-to-consumer (DTC) marketing is significant, and it really starts the conversation, raises awareness, and makes the surgeon’s task easier, panelists agreed.

“I don’t have to go through a 30-minute talk on the aging changes of the face and why you need mid-facial filler and filler into the temple, and filler into the jawline, and filler into the chin, when they’ve already been prepped before they come in because the company is now advertising,” Dr. Fabi said.

Dr. Yoelin agreed. “Patients may have some preconceived notions about what they think are the best courses of action for themselves. Simply starting conversations to introduce the complete set of options available to them definitely helps me as a practitioner.”

NEUROMODULATOR INNOVATION

There has been an influx of new fillers, but there hasn’t been much innovation or diversity in terms of neuromodulators, the panelists agreed. As it stands, there are three botulinum toxin Type A (BoNTA) products available for cosmetic treatments: onabotulinumtoxinA (Botox™, Allergan), abobotulinumtoxinA (Dysport™, Galderma), and incobotulinumtoxinA (Xeomin™, Merz Aesthetics). (See Table 2)

These all behave in similar fashion, but there probably are small differences that can be teased out. With adequate differentiation, it would be easier to customize treatments with neuromodulators as doctors now do with soft tissue fillers. The hope is that a novel neurotoxin will come to market in the United States in the next several years—whether serotype B or even E.

There is already some innovation taking place, with companies investing in longer acting serotype A products as well as neuro-

TABLE 1

Trade Name	Material	Applicant	Decision Date	Approved For
ARTEFILL	Polymethylmethacrylate Beads, Collagen and Lidocaine.	Suneva Medical, Inc.	10/27/2006	Use in facial tissue around the mouth (i.e., nasolabial folds).
BELOTERO BALANCE	Hyaluronic Acid	Merz Pharmaceuticals	11/14/2011	Injection into facial tissue to smooth wrinkles and folds, especially around the nose and mouth (nasolabial folds).
CAPTIQUE INJECTABLE GEL	Hyaluronic Acid	Genzyme Biosurgery	11/12/2004	Injection into the mid to deep dermis for correction of moderate to severe facial wrinkles and folds (such as nasolabial folds).
COSMODERM 1	Collagen	Inamed Corporation	3/11/2003	Injection into the superficial papillary dermis for correction of soft tissue contour deficiencies, such as wrinkles and acne scars.
ELEVESS	Hyaluronic Acid with Lidocaine	Anika Therapeutics	12/20/2006	Use in mid to deep dermis for correction of moderate to severe facial wrinkles and folds (such as nasolabial folds).
EVOLENCE COLLAGEN FILLER	Collagen	Colbar Lifescience I	6/27/2008	The correction of moderate to deep facial wrinkles and folds (such as nasolabial folds).
FIBREL	Collagen	Serono Laboratories	2/26/1988	The correction of depressed cutaneous scars which are distendable by manual stretching of the scar borders.
HYLAFORM (HYLAN B GEL)	Modified hyaluronic acid derived from a bird (avian) source	Genzyme Biosurgery	4/22/2004	Injection into the mid to deep dermis for correction of moderate to severe facial wrinkles and folds (such as nasolabial folds).
JUVÉDERM 24HV, JUVÉDERM 30, and JUVÉDERM 30HV	Hyaluronic Acid	Allergan	6/2/2006	Use in mid to deep dermis for correction of moderate to severe facial wrinkles and folds (such as nasolabial folds).
JUVÉDERM ULTRA XC AND JUVÉDERM ULTRA PLUS XC	Hyaluronic Acid with Lidocaine	Allergan	1/7/2010	The addition of 0.3% Lidocaine into Juvéderm Ultra and Juvéderm Ultra Plus.
JUVÉDERM VOLBELLA XC	Hyaluronic Acid with Lidocaine	Allergan	5/31/2016	Injection into the lips for lip augmentation and for correction of perioral rhytids in adults over the age of 21.
JUVÉDERM VOLLURE XC	Hyaluronic Acid	Allergan	3/17/2017	Injection into the mid to deep dermis for correction of moderate to severe facial wrinkles and folds (such as nasolabial folds) in adults over the age of 21.
JUVÉDERM VOLUMA XC	Hyaluronic Acid with Lidocaine	Allergan	P110033	Deep (subcutaneous and/or supraperiosteal) injection for cheek augmentation to correct age-related volume deficit in the mid-face in adults over the age of 21.
PREVELLE SILK	Hyaluronic Acid with Lidocaine	Genzyme Biosurgery	P030032 S007	Injection into the mid to deep dermis for correction of moderate to severe facial wrinkles and folds (such as nasolabial folds).
RADIESSE	Hydroxylapatite	Bioform Medical, Inc.	P050052/S049	Subdermal implantation for hand augmentation to correct volume loss in the dorsum of the hands.
RADIESSE 1.3CC AND 0.3CC	Hydroxylapatite	Bioform Medical, Inc	P050037	Restoration and/or correction of the signs of facial fat loss (lipoatrophy) in people with HIV.
RADIESSE 1.3CC AND 0.3CC	Hydroxylapatite	Bioform Medical, Inc	P050052	Subdermal implantation for correction of moderate to severe facial wrinkles and folds (such as nasolabial folds).

TABLE 1 (continued)

Trade Name	Material	Applicant	Decision Date	Approved For
RESTYLANE INJECTABLE GEL	Hyaluronic Acid	Medicis Aesthetics Holdings, Inc	P040024 S051	Lip augmentation in those over the age of 21 years.
RESTYLANE INJECTABLE GEL	Hyaluronic Acid	Medicis Aesthetics Holdings, Inc	P040024	Injection into the mid to deep dermis for correction of moderate to severe facial wrinkles and folds (such as nasolabial folds).
RESTYLANE INJECTABLE GEL	Hyaluronic Acid	Q-med Ab	P020023	Injection into the mid to deep dermis for correction of moderate to severe facial wrinkles and folds (such as nasolabial folds).
RESTYLANE LYFT WITH LIDOCAINE	Hyaluronic acid with lidocaine	Galderma Laboratories	P040024 S073	Moderate to severe facial folds and wrinkles or in patients over the age of 21 who have age-related volume loss.
RESTYLANE SILK	Hyaluronic Acid with Lidocaine	Valeant Pharmaceuticals North America LLC/ Medicis	P040024 S072	Indicated for lip augmentation and dermal implantation for correction of perioral rhytids (wrinkles around the lips) in patients over the age of 21.
RESTYLANE-L INJECTABLE GEL	Hyaluronic Acid with Lidocaine	Medicis Aesthetics Holdings, Inc.	P040024 S056	Injection into the mid to deep dermis for correction of moderate to severe facial wrinkles/ folds (such as nasolabial folds) and for lip augmentation in those over the age of 21 years.
SCULPTRA	Poly-L-Lactic Acid (PLLA)	Sanofi Aventis U.S.	P030050	Restoration and/or correction of the signs of facial fat loss (facial lipoatrophy) in people with Human Immunodeficiency Virus (HIV).
SCULPTRA AESTHETIC	Poly-L-Lactic Acid (PLLA)	Sanofi Aventis U.S.	P030050 S002	Use in shallow to deep nasolabial fold contour deficiencies and other facial wrinkles.
ZYDERM COLLAGEN IMPLANT	Collagen	Allergan	P800022	Use in the dermis for correction of contour deficiencies of this soft tissue.
ZYPLAST(R)	Collagen	Collagen Corp.	P800022 S011	Use in mid to deep dermal tissues for correction of contour deficiencies.

Source: FDA.gov

TABLE 2. BOTULINUM TOXINS IN THE US

Product	FDA Status	Cosmetic Indication?
BOTOX (onabotulinumtoxinA)	Approved	Yes
DYSPORT (abobotulinumtoxinA)	Approved	Yes
XEOMIN (incobotulinumtoxinA)	Approved	Yes
MYOBLOC (rimabotulinumtoxinB)	Approved	No
RT002 (DaxibotulinumtoxinA)	Phase 2 complete	In development

modulators with shorter-lasting effects and/or quicker onset of effects. If the field evolved to produce a variety of different toxins that behave in different ways, it would only improve upon cosmetic results and satisfaction, and allow surgeons to adopt a similar customized approach as is currently seen with fillers.

There's a lot of room for innovation with formulation and also application, Dr. Shridharani said. "I suspect that we haven't seen the last of neuromodulators and what they can do, other than just targeting muscle groups."

NECESSITY IS THE MOTHER OF INVENTION

The many ways in which aesthetic surgeons utilize neuromodulators in practice have already evolved. "The medical aesthetic community has developed novel product applications. Now, in addition to addressing lines and wrinkles, we can use the products to improve contours and facial shapes," Dr. Yoelin said.

"I use a good deal of neurotoxin for masseter injection off-label as well as for the depressor anguli oris, mentalis, and then for the jawline," Dr. Fabi said. "The ability to contour and slim the lower

Courtesy Sabrina Fabi, MD

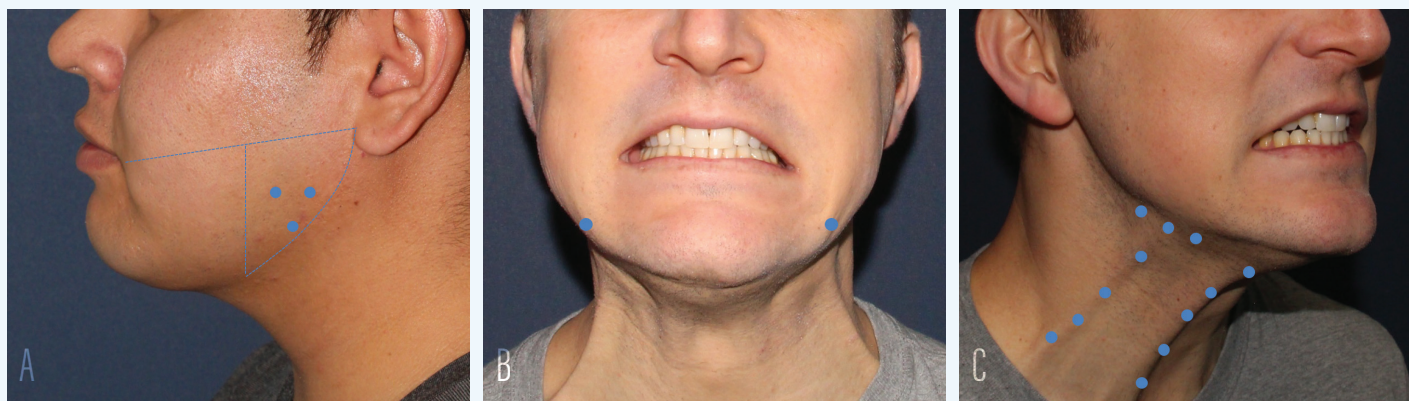


Figure 1A. The blue dotted line denotes the recommended borders of injection. A line can be drawn superiorly from the oral commissure to the lower insertion of the tragus, anteriorly by the anterior border of the masseter, and inferiorly and laterally by the angle of the mandible and posterior masseter. Injections should be kept 1cm posterior to the anterior border to avoid diffusion into muscles of facial expression. **Figure 1B.** The DAO can be identified by having the patient show their bottom teeth. The injection point is commonly 1cm posterior to a line extending from the nasolabial fold to the angle of the mandible. Classically 4 units of onabotulinumtoxin A or 12 units of abobotulinumtoxin A are placed into each DAO. This patient would benefit with more on his left than his right DAO. **Figure 1C.** For platysmal bands, injections are placed superficially spaced every 2cm along each cord, with 2 units of onabotulinumtoxin A or 6 units of abobotulinumtoxin A into each injection point. The superior row of injection points along the mandible receives 4 units of onabotulinumtoxin A or 12 units of abobotulinumtoxin A into each injection point to provide greater jawline definition. (*Dermatol Surg.* 2017;43(8):1042-1049.)

Courtesy Jason Bloom, MD

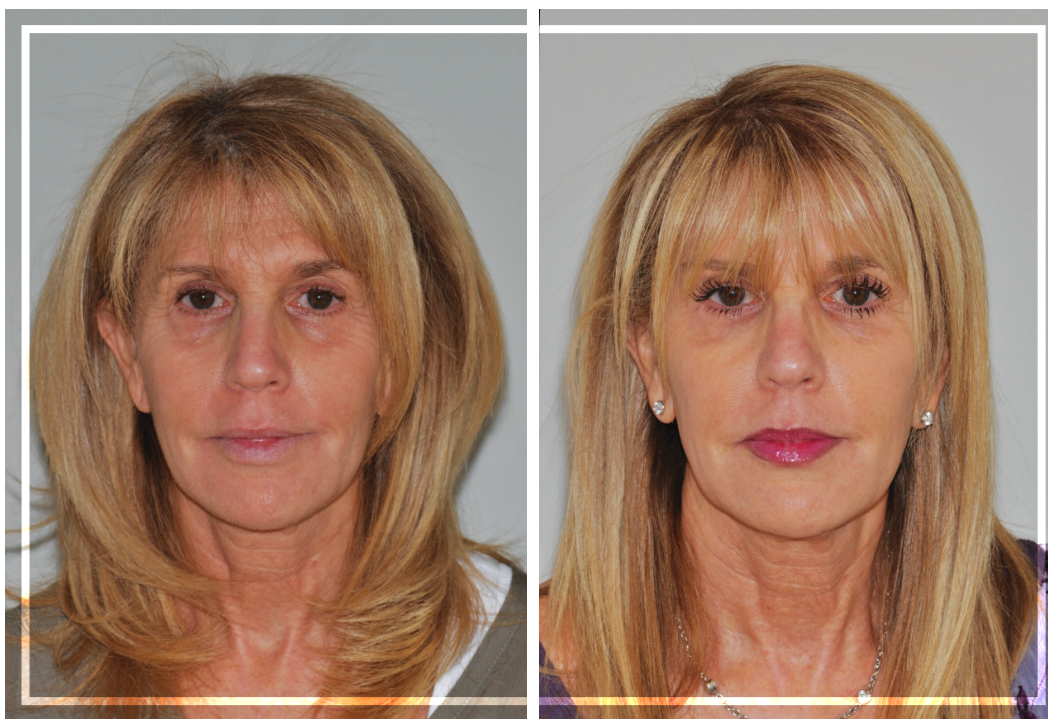

Figure 2. Before (left) and after (right) series of treatments. Treatment 1: 2 vials of Sculptra (Galderma) each at Week 1 and Week 6. Treatment 2 (3 months later): 1 syringe of Juvéderm Voluma (Allergan) to the midface, 20 units of Botox (Allergan) to the glabella, 5 units to the frontalis, and 10 units to each lateral orbicularis oculi. Treatment 3 (3 months later): Full-face fractionated CO₂ laser resurfacing.

face with neuromodulator in the masseter is a nice tool that then really changes proportions and doesn't require all this filler in the mid-face for the contour effect."

Dr. Fabi will also inject neuromodulator along the platysma

muscle and the depressor anguli oris (DAO) to define the jawline and soften the melomental fold in some patients.

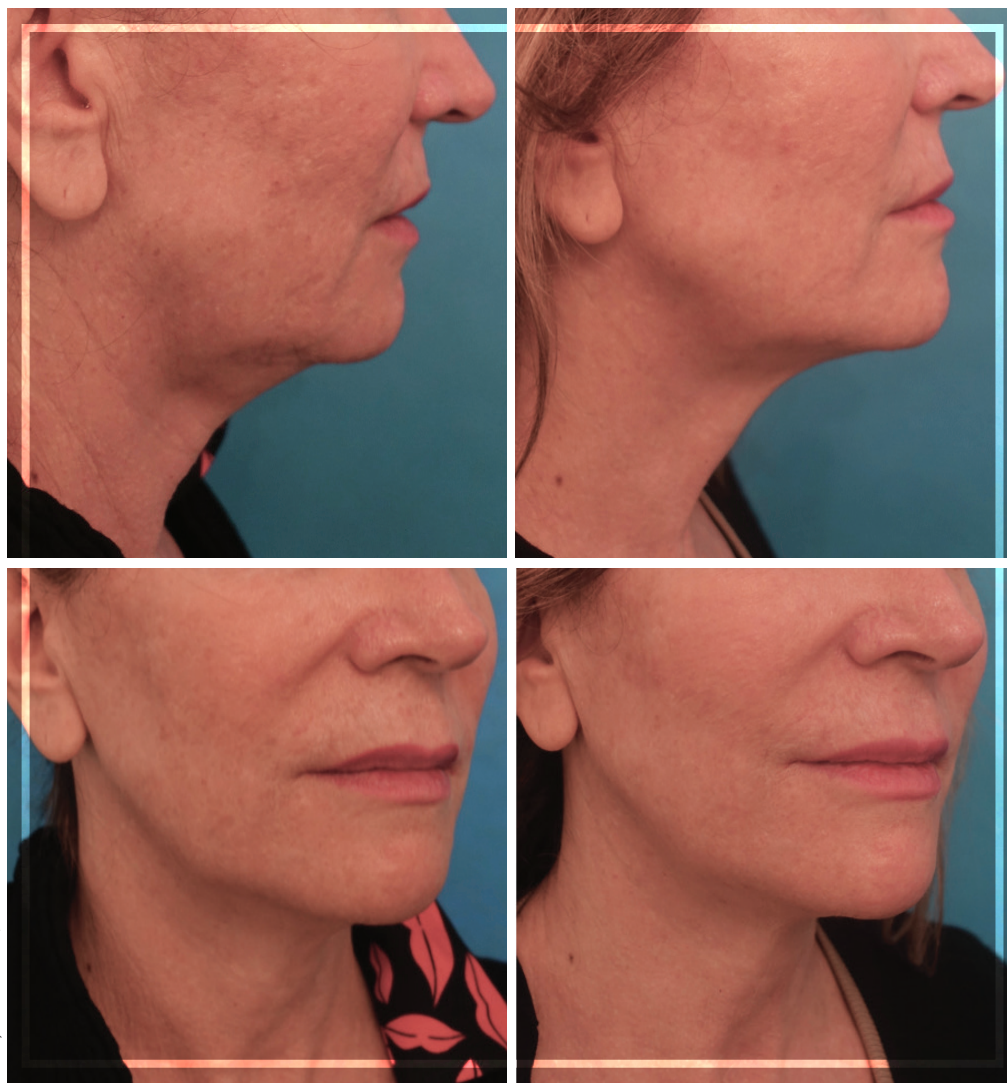"I always tell my patients, instead of adding filler, I'm just subtracting with a little bit of neuromodulator." (Figure 1)

Dr. Bloom is performing significantly fewer surgical brow lifts. Instead, he raises brows by weakening the brow depressor muscles with a neuromodulator. "I tell patients it's not necessarily for the lines, it's more to open your eyes to give some more life back to the eyes," he said. In addition, he is using more neuromodulator products in the lower face than he had been doing previously, specifically in the masseters to slim the face and platysmal bands along the jawline.

Studies have demonstrated that BoNTA stimulates neocollagenesis and improves skin pliability and elasticity. Improvement in dermal architecture and biomechanical properties helps to smoothe static lines, Dr. Fabi said. The unanswered question is whether this is a result of the drug itself or a controlled wound healing process jumpstarted by the injection.

Dr. Fabi also has patients report a decrease in acneiform lesions

Dr. Fabi also has patients report a decrease in acneiform lesions



Courtesy Sachin Shridharani, MD

Figure 3. 65-year-old patient at baseline (left) and after 1 treatment with 4 vials submental, jowl, and jawline filler with Juvéderm Voluma (Allergan).

on their forehead after neuromodulator injections in the area. This begs the question why? There are many possibilities, including the fact that relaxing the underlying muscle and thereby overlying skin may enhance light reflection off the skin, giving the appearance of improved skin quality, or there may be an effect on the sebaceous glands that has not been elucidated.

Having a wider variety of neuromodulators—even just serotype A products—is helpful for patients who may have had a less than ideal experience or outcome with one.

“It’s nice to be able to switch them to something if they have a bad experience or feel one neuromodulator didn’t ‘take effect or last as long’ even if it’s related more to poor injection technique or reconstitution practices than the actual drug,” Dr. Fabi said.

In a small pilot trial performed at Dr. Fabi’s practice, patients switched from Botox Cosmetic to Dysport within her practice. One third of those patients actually preferred Dysport, one-third still preferred their Botox, and the final third couldn’t tell the difference.

SUBMENTAL FAT REDUCTION WITH DEOXYCHOLIC ACID

One of the most challenging areas to treat, especially without surgery, is the jawline. The introduction of deoxycholic acid (Kybella, Allergan), as a new injectable in a category all of its own in April 2015, expanded the way aesthetic doctors address the aging face.

Before Kybella, surgeons could camouflage the area or sweep it under the rug by injecting filler into the lateral portion of the jaw (including pre- and post-jowl sulcus).

Now it’s not about adding volume, but also about subtracting it to slim down the submental region. “You can reduce the volume submentally and also off-label along the jowls,” Dr. Fabi said. “You can only put so much dermal filler in the mid-face and jawline, or even in the lateral cheek, to pick up that subcutaneous fat of the jowls, so with Kybella I’m able to reduce that fat without necessarily having to put all this filler around the area to pick it up. It’s a nice adjunct to what we do.”

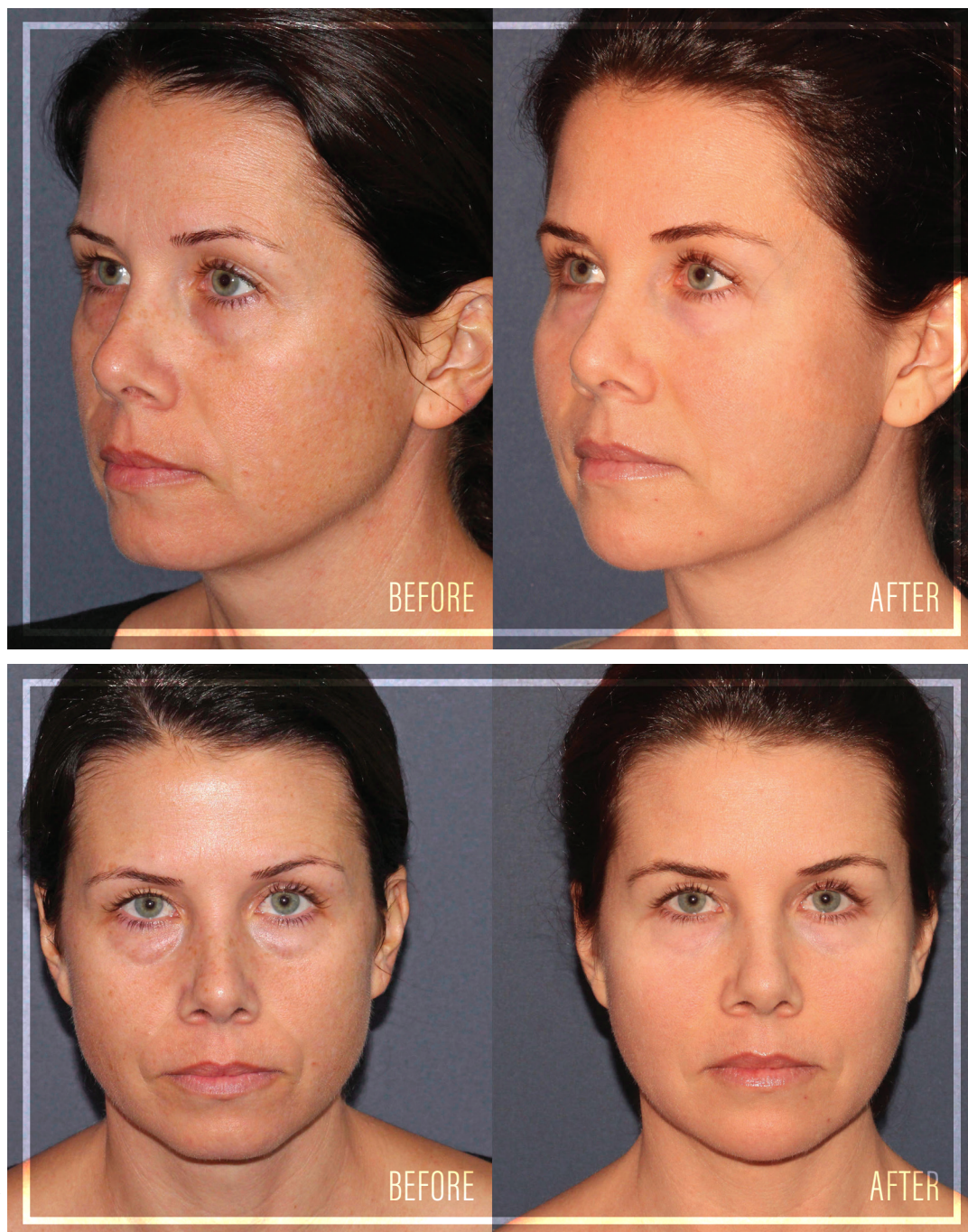
Dr. Bloom said that Kybella has really resonated with patients. Today’s aesthetic patient understands the idea of injectables. “I tell patients we can do surgery, liposuction, cryolipolysis, or injectable radiofrequency. I say we can heat it, cool it, inject it, or suction it, but if I explain to patients that

we’re going to give you volume with fillers through an injection and weaken some of your glabellar muscles with injections, and then we’re going to take care of that double chin and help contour your neck with an injection, it resonates,” he said.

Kybella provides practitioners with another non-invasive tool to support complete facial rejuvenation, Dr. Yoelin said. “Now, practitioners can non-invasively remove unwanted jowling and submental fullness to improve patients’ jawlines and necklines, respectively.”

Deoxycholic acid fills an important niche for today’s aesthetic patient. “We have a lot of devices for non-surgical body contouring, fat reduction, whether it’s CoolSculpting, LipoSonic, UltraShape, or Vanquish and can do liposculpture, but even with all of those modalities, patients are always looking for something they can do quickly at the bedside, that takes two minutes, doesn’t tie them up here at the practice for an hour or two hours,” Dr. Fabi said.

Enter deoxycholic acid. “The nice thing about Kybella and



Courtesy Sabrina Fabi, MD

Figure 4: A 38-year-old before (left) and after (right) Juvéderm Voluma (Allergan) injections to her cheek, jawline and chin; Belotero (Merz Aesthetics) to tear trough, CO₂ laser resurfacing around eyes, IPL to face/neck, and Dysport (Galderma) to upper face, masseters, and DAO.

deoxycholic acid is that if you treat a patient correctly, it works every time,” Dr. Bloom said. “There’s no on or off switch. It’s either in or it’s not. If you treat a patient, if you put this injectable product in there, it will dissolve fat.”

Unfortunately, the same thing can’t be said about other cosmetic treatments and technologies. “If we do a couple of treatments, it will work every time so I don’t have to explain that I’m

not sure it will work 20 percent of the time,” Dr. Bloom said.

Dosing matters, too, Dr. Fabi adds. “This is something that’s really dose dependent,” she said. “You have to use enough to treat the entire surface area you are trying to reduce. If it’s a little bit of swelling that comes with it, that’s fine. Patients with realistic expectations about swelling will tolerate swelling if it means an excellent result.”

Dr. Shridharani agreed. “Staying therapeutic is key and is essential.” Using just one vial, for example, will produce sub-optimal results. “You’re giving them all the pain without the pleasure. They’re still going to swell. They’re still going to be uncomfortable, but they won’t get the benefit.”

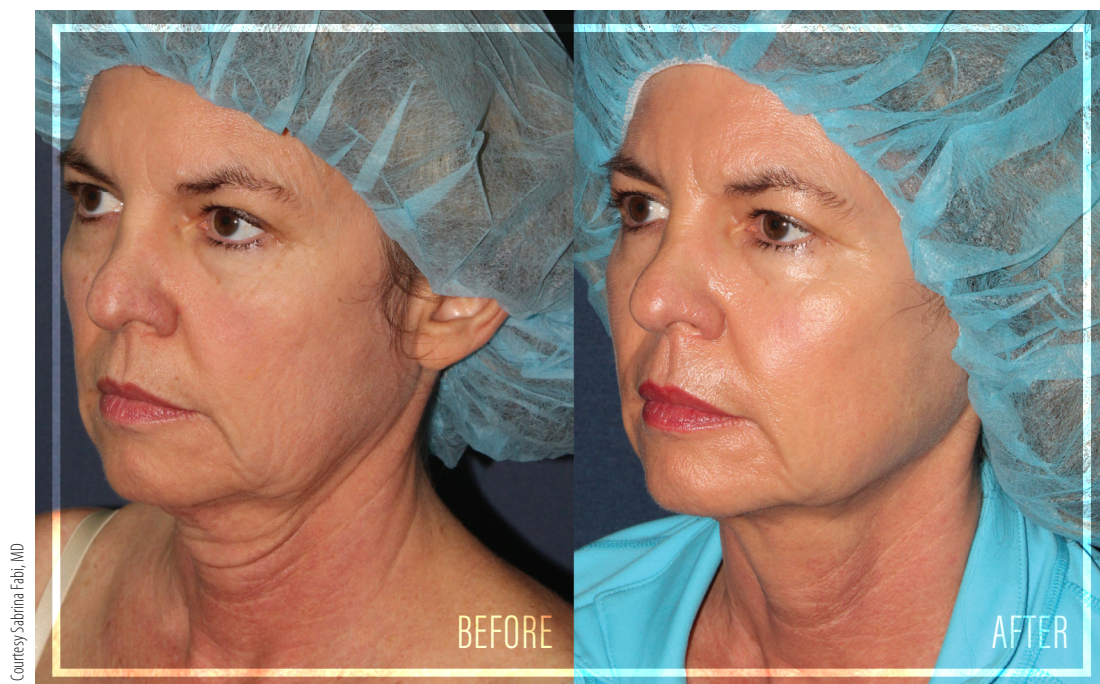Kybella results are permanent. Patients don’t need to come back repeatedly for maintenance treatments. “Think of this as neck contouring, or it’s a surgery in a syringe, because those are all the buzz words that we use in my practice to help patients understand that they are going to do this a few times and you’re done,” Dr. Shridharani said.

With the promise of permanent results, patients are more willing to tolerate the downtime and cost associated with Kybella.

SMART COMBINATIONS

Combining minimally invasive modalities allows surgeons to get patients closer to the type of cosmetic results previously only attainable with surgery. For example, Dr. Fabi often com-

bines Kybella with Ultherapy (Merz Aesthetics) to improve the jawline. “The average age for someone coming in with some laxity, at least in our practice and in most of the trials, has always been about 55, 56 for submental laxity,” she said. “There is definitely a component of laxity, and Ultherapy is a device that is approved for a non-surgical lift of the submental area, but there’s always been a component of fat, too, so now I have something that



Courtesy Sabrina Fabi, MD

Figure 5. A 55-year-old before (left) and 1 year after (right) one Ultherapy (Merz Aesthetics) treatment to lower face and neck and Juvéderm Voluma (Allergan) to cheeks and chin/prejowl sulcus.

allows me to target the skin element as well as the submental fat.”

Generally, Dr. Fabi starts with Ultherapy then immediately followed by Kybella, on the same day. “I do believe that there’s probably some synergy taking place because of the inflammatory cascade that ensues,” she said. More research is needed to support and corroborate this hypothesis.

“We know from histologic studies with Kybella that there was a thickening of collagen bundles that occurred after injection as a result of associated inflammation,” she said. This also occurs with Ultherapy.

When combining therapies, Dr. Yoelin tends to inject Kybella at the end of the appointment so the patient can return home soon afterward.

“Before treating with Kybella, I will still use other products in other areas of the face during the same patient visit if necessary for efficiency,” he said.

“I will typically avoid mixing or injecting a product in areas where I also inject Kybella due to some concern about how the products might react to one another,” he said.

There is no reliable way to gauge what would happen if deoxycholic acid interacted directly with another product, the panelists add. For now, most injectors are taking the “better safe than sorry” route.

But timing aside, the possibilities of combinations are exponential. When it comes to the minimally invasive tools and technologies, the sum is almost always greater than the parts. “There can be a fair amount of skin tightening that we see after deoxycholic acid injections, mainly because of the deep inflammation that you get, and this can be augmented with radiofrequency microneedling or transcutaneous radiofrequency,” Dr. Bloom said.

SHOW AND TELL: THE KEY TO EXPECTATION MANAGEMENT

It’s a whole new world for doctors and patients today, and perhaps the best way to explain to patients what they can expect in terms of downtime as well as results is to show before, during, middle, and after photos, the panelists said.

“When we verbalize things, people can interpret things so differently. For some, they thought, ‘Oh, my God, I thought that was going to be so much worse than you described,’” Dr. Fabi said. “And others are like, ‘Oh wow, I didn’t realize it was going to be like this. Using photos eliminates any possible confusion and makes sure everyone is on the same page regarding downtime and results.’”

This is why Dr. Fabi always shows and tells. “I always show photos when I verbalize an expectation to my patient, whether it is a result or downtime. Just so that there are no hidden surprises and they feel truly, strongly aware of what to expect,” she said.

PATIENTS JUST WANT TO KNOW EXACTLY WHAT TO EXPECT

Dr. Bloom does the same. “I tell them, ‘I’m going to show you the whole story, not just read you the first sentence and the last sentence of the story,’” he said. “I’m going to show you what patients look like at three days. I show them what patients are going to look like at a week. I show them what patients are going to look like at two weeks. And then at a month.”

Give them the worst case scenario, he said. “I show them the swelling that we see with deoxycholic acid. I show them bruising that they can get after filler because when you give it to them up front, then they can plan their schedule around it.”

Dr. Shridharani learned this lesson the hard way with CO₂ laser resurfacing patients. “I would say, ‘You’re going to look great after it’s all fully healed. But initially, you will look like a burn victim.’ So they were like, ‘Okay, great,’” he recalls.

“Then they did it and about three days later, they were horrified. I said, ‘Have you ever seen a good-looking burn victim? What did you expect?’”

To avoid these scenarios, he curated a library of photos depicting the entire recovery trajectory. The best way to explain recovery to patients is to use visual cues.

There are other roles for photos in an aesthetic practice as well, the panelists agreed. All panelists say that they show patients their own before and afters throughout the course of treatments so

Courtesy Sabrina Fabi, MD

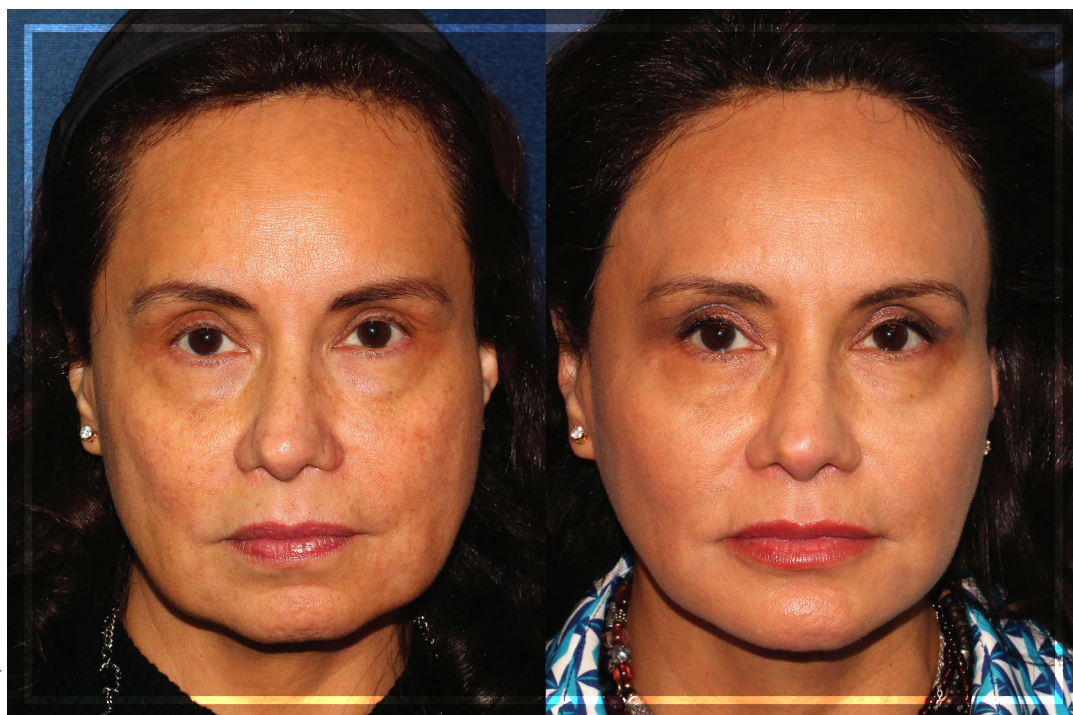

Figure 6. A 60-year-old before (left) and 1 year after (right) Ultherapy (Merz Aesthetics), Clear and Brilliant Permea (Solta Medical), Juvéderm Voluma (Allergan) to cheeks, Radiesse (Merz Aesthetics) to jawline, Restylane Lyft (Galderma) to chin/prejowl sulcus, Restylane Silk (Galderma) to lips, and Botox (Allergan) to masseters, DAO, and upper face.

that patients can truly appreciate how far they have come.

"It is good to show them their before and after photos, even if they're completely opposed to seeing them and they don't want to remember just to give them the perspective that look how far we've come," Dr. Bloom said.

"I use the exercise of looking at photos to remind patients that we've come very far and maybe they're not necessarily getting as dramatic of a result, from one before and after to another, in the last three months. But if you look at them in the last seven years, they look better than when they started," Dr. Bloom said.

It's about achieving natural looking results, Dr. Fabi said. Photography helps keep things real, and prevents a "perception shift" from taking place, as patients quickly forget where they started. It can also help prevent patients from going overboard and doing more than they really need, which can be a slippery slope for some patients.

"I call it my 401(k) plan for the skin because you're building collagen for the future," said Dr. Bloom. "With before and afters, I can say, 'You're four years older in this after picture here, but you still look better than the day that you came in the office.'"

Photos allow doctors to show patients how much they have improved with time.

Dr. Yoelin added that photos allow doctors to evaluate their

own work, too. "Photos allow me to evaluate my past performance and contemplate the best approaches to various patient scenarios," he said.

THE BIG PICTURE

Aesthetic facial procedures do more than change how patients look, they change how they see themselves and how others perceive them as well. "We really are in the self-esteem field. It's very rewarding to improve the lives of my patients," said Dr. Yoelin.

Advances in technologies and techniques have made it possible for aesthetic doctors to reach even more individuals, and restore beauty and thus self-esteem, or create it anew, without surgery. The landscape has changed dramatically in a very short time, and the future of facial aesthetics is ripe with even greater possibilities. ■

1. Shridharani SM. Early Experience in 100 Consecutive Patients With Injection Adipocytolysis for Neck Contouring With ATX-101 (Deoxycholic Acid). *Dermatol Surg.* 2017 Jul;43(7):950-958.
2. Gierloff M, et al. Aging changes of the midfacial fat compartments: a computed tomographic study. *Plast Reconstr Surg.* 2012;129:263.
3. Shaw RB, et al. Aging of the facial skeleton: aesthetic implications and rejuvenation strategies. *Plast Reconstr Surg.* 2011;127:374.
4. Lam SM, et al. Analysis of facial aesthetics as applied to injectables. *Plast Reconstr Surg.* 2015;136:115.
5. Sundaram H, et al. Cohesivity of hyaluronic acid fillers: development and clinical implications of a novel assay, pilot validation with a five-point grading scale, and evaluation of six U.S. Food and Drug Administration–approved fillers. *Plast Reconstr Surg.* 2015;136:678.
6. Ramanadham SR, et al. Newer understanding of specific anatomic targets in the aging face as applied to injectables: superficial and deep facial fat compartments—an evolving target for site-specific facial augmentation. *Plast Reconstr Surg.* 2015;136(5 Suppl):49S-55S.
7. Landau M, et al. Science of hyaluronic acid beyond filling: fibroblasts and their response to the extracellular matrix. *Plast Reconstr Surg.* 2015;136:188S.
8. Rohrich RJ, et al. The fat compartments of the face: anatomy and clinical implications for cosmetic surgery. *Plast Reconstr Surg.* 2007;119:2219.
9. Rohrich RJ, et al. The youthful cheek and the deep medial fat compartment. *Plast Reconstr Surg.* 2008;121:2107.
10. Oh SH, Lee Y, Seo YJ, et al. The potential effect of botulinum toxin type A on human dermal fibroblasts: an in vitro study. *Dermatol Surg.* 2012;38(10):1689-1694.
11. Bonaparte JP, Ellis D. Alterations in the elasticity, pliability and viscoelastic properties of facial skin after injection of onabotulinum toxin A. *JAMA Facial Plast Surg.* 2015 Jul-Aug;17(4):256-63.
12. Soft-Tissue Fillers and Neuromodulators: International and Multidisciplinary Perspectives 5S. *Plast Reconstr Surg.* November 2015; 136(5S)

INSTRUCTIONS FOR CME CREDIT

To receive *AMA PRA Category 1 Credit*,™ you must complete the Post Test and Activity Evaluation and mail or fax to Evolve Medical Education LLC; PO Box 358, Pine Brook, NJ 07058; Fax: (610) 771-4443. To answer these questions online and receive real-time results, please visit evolvemeded.com and click "Online Courses." If you are experiencing problems with the online test, please email us at support@evolvemeded.com. Certificates are issued electronically, please provide your email address below.

Please type or print clearly, or we will be unable to issue your certificate.

Name _____ ☐ MD participant ☐ non-MD participant

Phone (required) _____ ☐ Email (required) _____

Address _____

City _____ State _____

BEYOND FACE VALUE

1 AMA PRA Category 1 Credit™

Expires August 30, 2018

1. Which of the following statements best characterizes the "triangle of youth" as a concept in female facial beauty and aging?
 - a. The youthful face draws attention at the eyes and cheek bones, tapering to the chin.
 - b. The youthful face draws attention at the cheeks and mid-face, tapering to the forehead.
 - c. The youthful face draws attention at a defined jaw and chin, tapering to the bridge of the nose.
2. True or False? The first dermal fillers on the market were collagen based and ideal for filling superficial lines and folds rather than providing deep volume.
 - a. True
 - b. False
3. Current efforts in the development of injectable neurotoxins are focused on:
 - a. Shorter duration of effect for enhanced "reversibility"
 - b. Longer onset for a more gradual improvement in appearance
 - c. Shorter onset and shorter duration of effect
 - d. Shorter onset and longer duration of effect
4. Injection of neurotoxin into the platysma muscle and the depressor anguli oris (DAO) is expected to:
 - a. Define the jawline and enhance the melomental fold
 - b. Define the jawline and soften the melomental fold
 - c. Soften the jawline and enhance the melomental fold
 - d. Soften the jawline and soften the melomental fold
5. Which of the following has been associated with an increase in collagen and elastin at the site of injection?
 - a. HA fillers
 - b. Botulinum toxin
 - c. Deoxycholic acid
 - d. Both a and b
 - e. Both b and c
6. When used in conjunction with deoxycholic acid injections in the submental area, radiofrequency (RF) devices:
 - a. Confer a cooling effect that makes injections more tolerable
 - b. Directly target fat to further promote fat destruction
 - c. Speed the elimination of destroyed fat cells
 - d. Provide a tightening effect on skin of the submental region

ACTIVITY EVALUATION

Did the program meet the following educational objectives?

Describe the properties of different injectable fillers and explain how these properties provide different lifting/filling effects.

Agree Neutral Disagree

Devise strategies for facial rejuvenation that employ the unique characteristics of different fillers to achieve complementary effects.

Identify opportunities for combination strategies for rejuvenation that optimize aesthetic outcomes, patient convenience, cost, and satisfaction.

Describe the potential effects of facial rejuvenation on the patient psyche and discuss possible impact on quality of life.

Utilize strategies to elicit patient desires and deliver combination approaches to facial rejuvenation that meet patient objectives.

Your responses to the questions below will help us evaluate this CME activity. They will provide us with evidence that improvements were made in patient care as a result of this activity as required by the Accreditation Council for Continuing Medical Education (ACCME).

Do you feel the program was educationally sound and commercially balanced? ____ Yes ____ No

Comments regarding commercial bias:

Rate your knowledge/skill level prior to participating in this course: 5 = High, 1 = Low _____

Rate your knowledge/skill level after participating in this course: 5 = High, 1 = Low _____

Would you recommend this program to a colleague? ____ Yes ____ No

Do you feel the information presented will improve/change your patient care? ____ Yes ____ No

Please identify how you will improve/change:

____ Change the management and/or treatment of patients. Please specify:

____ Create/revise protocols, policies, and/or procedures. Please specify:

Please identify any barriers to change.

____ Cost

____ Lack of time to assess/counsel patients

____ No barriers

____ Lack of consensus or professional guidelines

____ Lack of opportunity (patients)

____ Other. Please specify: _____

____ Lack of administrative support

____ Reimbursement/insurance issues

____ Lack of experience

____ Lack of resources (equipment)

____ Patient compliance issues

This information will help evaluate this CME activity, we may contact you by e-mail in 1-2 months to see if you have made this change? If so, please provide your e-mail address below.

Modern
Aesthetics®


evolve
medical education