

Supplement to

April 2017

AOC

Advanced Ocular Care

COPE CE Activity

Updates on Ocular Surface Disease, Glaucoma, and Cataract Comanagement

John D. Gelles, OD
Scott G. Hauswirth, OD
Josh Johnston, OD
Brett King, OD
Nate Lighthizer, OD
Justin Schweitzer, OD

Release Date: March 2017; Expiration Date: March 2020
This course is COPE approved for 1.0 hours of CE credit for optometrists.
COPE Course ID: 53827-AS
COPE Event ID: 113393



This continuing education activity is supported through unrestricted educational grants from Aerie Pharmaceuticals, Alcon, Bausch + Lomb, Bio-Tissue, Glaukos Corporation, Marco, ScienceBased Health, and Shire.

Administrator


evolve
medical education

Sponsored by

UNIVERSITY of
HOUSTON

Release Date: March 2017
Expiration Date: March 2020

COPE Course ID: 53827-AS
COPE Event ID: 113393

FACULTY

John D. Gelles, OD
Scott G. Hauswirth, OD
Josh Johnston, OD
Brett King, OD
Nate Lighthizer, OD
Justin Schweitzer, OD

LEARNING METHOD

This educational activity consists of a supplement and 10 study questions. To obtain credit, the participant should read the learning objectives, read the material, answer all questions in the post test, and complete the activity evaluation form. This educational activity should take a maximum of 1.0 hours to complete.

CONTENT SOURCE

This continuing education (CE) activity captures content from the 1st Annual Intrepid CE-accredited Symposium held in October 2016 in Miami, FL.

TARGET AUDIENCE

The target audience for this CE activity is optometrists.

LEARNING OBJECTIVES

After successfully completing this activity, optometrists will have improved their ability to:

- Recognize the importance of early diagnosis and treatment of dry eye disease
- Assess the role of inflammatory markers/processes in corneal disorders
- Formulate strategies to best treat corneal diseases based on the presence of comorbid conditions and/or risk factors
- Evaluate disease progression by using novel imaging devices
- Identify emerging classes of drugs and their potential advantages over currently used treatment paradigms
- Evaluate the safety and efficacy of different treatment

modalities for ocular hypertension and primary open-angle glaucoma

- Discuss future developments and direction of therapeutics for managing glaucoma

ACCREDITATION DESIGNATION STATEMENT

This course is COPE approved for 1.0 hour of CE credit for optometrists.

DISCLOSURES



John D. Gelles, OD, has had a financial agreement or affiliation during the past year with the following commercial interests in the form of *Consultant/Advisory Board/Speaker's Bureau*: Blanchard Lab.

Stock: EyecareLive. *Advisory Board/Speaker's Bureau*: Bio-Tissue.

Consultant: Contamac; and Formulens. *Speaker's Bureau*:

Visionary Optics.



Scott G. Hauswirth, OD, has had a financial agreement or affiliation during the past year with the following commercial interests in the form of *Consultant/Advisory Board/Speaker's Bureau*: Allergan;

Bausch + Lomb; Bio-Tissue; Shire; and TearScience.



Josh Johnston, OD, has had a financial agreement or affiliation during the past year with the following commercial interests in the form of *Consultant*: Alcon; Allergan; Bio-Tissue; Johnson & Johnson Vision; and

Shire. *Speaker's Bureau*: Alcon; Allergan; Bio-Tissue; and Shire.



Brett King, OD, has no financial agreements or affiliations during the past year.



Nate Lighthizer, OD, has had a financial agreement or affiliation during the past year with the following commercial interests in the form of *Consultant/Advisory Board/Speaker's Bureau*: Aerie Pharmaceuticals; Alcon; Bio-Tissue; Diopsys; Johnson & Johnson Vision; and Shire.



Justin Schweitzer, OD, has had a financial agreement or affiliation during the past year with the following commercial interests in the form of *Consultant*: Alcon; Allergan; Bausch + Lomb; Bio-Tissue; Glaukos Corporation; Reichert; and TearScience. *Speaker's Bureau*: Allergan; Bausch + Lomb; and Glaukos Corporation.

EDITORIAL SUPPORT DISCLOSURE

Cheryl Cavanaugh, MS, director of operations, Evolve Medical Education LLC; and Michelle Dalton, medical writer, have no real or apparent conflicts of interest to report. Rishi P. Singh, MD, peer reviewer, has had a financial agreement or affiliation during the past year with the following commercial interests in the form of *Consultant/Advisory Board/Speaker's Bureau*: Alcon; Allergan; Genentech; Optos Plc; and Regeneron Pharmaceuticals. *Grant/Research Support*: Alcon; Apellis Pharmaceuticals; Carl Zeiss Meditec; Genentech; and Regeneron Pharmaceuticals.

DISCLOSURE ATTESTATION

Each of the contributing physicians listed above has attested to the following: (1) that the relationships/affiliations noted will not bias or otherwise influence his or her involvement in this activity; (2) that practice recommendations given relevant

to the companies with whom he or she has relationships/affiliations will be supported by the best available evidence or, absent evidence, will be consistent with generally accepted medical practice; and (3) that all reasonable clinical alternatives will be discussed when making practice recommendations.

PRODUCT USAGE IN ACCORDANCE WITH LABELING

Please refer to the official product information for each product for discussion of approved indications, contraindications, and warnings.

GRANTOR STATEMENT

This COPE CE activity is supported through an unrestricted educational grant from Aerie Pharmaceuticals, Alcon, Bausch + Lomb, Bio-Tissue, Glaukos Corporation, Marco, ScienceBased Health, and Shire.

DISCLAIMER

The views and opinions expressed in this educational activity are those of the faculty and do not necessarily represent the views of Evolve Medical Education LLC, *Advanced Ocular Care*, Aerie Pharmaceuticals, Alcon, Bausch + Lomb, Bio-Tissue, Glaukos Corporation, Marco, ScienceBased Health, or Shire.

Go to evolvemeded.com/online-courses/ to view the online version of this supplement.



Scleral Lenses as an Adjunctive Therapy in OSD

Tricks and tips for successful therapeutic scleral lens wear in ocular surface disease.

By John D. Gelles, OD, FIAO, FCLSA

Scleral lenses are predominantly used for visual rehabilitation of irregular corneal conditions (keratoconus, pellucid marginal degeneration, post-LASIK ectasia, etc), and for therapeutic treatment of severe/complex ocular surface disease (OSD) (neurotrophic keratitis, graft-versus-host disease, ocular cicatricial pemphigoid, etc). In the latter, these lenses are used as an adjunctive therapy to provide ocular protection and continuous lubrication.¹⁻⁷ Used in this manner, scleral lenses can prevent tissue desiccation and mechanical damage, can promote healing, and can disrupt the pain cycle—all of which greatly benefit the patient.

When considering the risk/benefit ratio, the best application for these lenses in OSD is as an adjunctive therapeutic treatment in severe/complex disease, when all other alternatives have been exhausted. In these cases, we may consider a scleral lens in lieu of surgery such as Gunderson flap, tarsorrhaphy, high-risk penetrating keratoplasty, or keratoprosthesis.⁸⁻¹¹

On the right patient, scleral lenses can be life-changing but are not risk or complaint-free. In my experience, the most common OSD patient complaint is foggy or cloudy vision for which three main sources exist: the lens surface, the post lens tear layer (PLTL), or the cornea. Thus, we are typically fighting poor lens wetting, lens deposits, chamber debris, corneal edema, and hypoxia.^{9,12,13}

THE LENS SURFACE

Poor front surface lens wetting will lead to visual fluctuation and poor visual performance. Poor wetting is usually caused by tear film instability or material properties, specifically high wetting angle. Most diseases that affect the tear film quality will adversely affect wetting (meibomitis, blepharitis, evaporative dry eye disease, etc) and must be treated before fitting a scleral lens (Figure 1).

Using alcohol-based cleaners

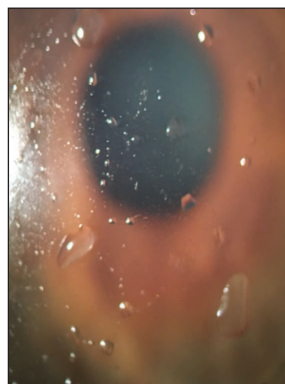


Figure 1. Poor lens wetting in patient with untreated meibomitis.

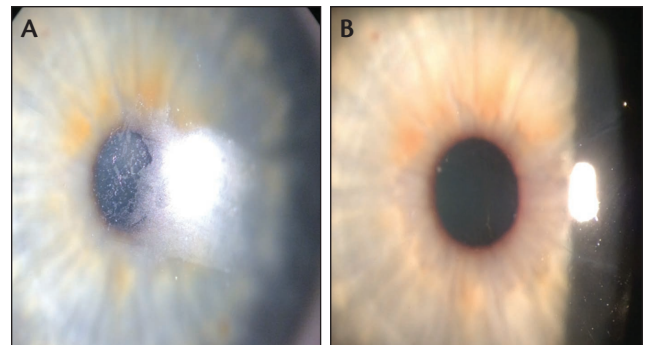


Figure 2. Pre-THP treatment: Note the hazy, frosted light reflex on the surface of the poorly wetting lens (A). Post-THP treatment: Note the clear, sharp light reflex of the now fully wetting lens surface (B).

and enzymatic cleaners can aid in improving the wettability by removing surface deposits. However, use abrasive cleaners with caution as these can prematurely wear lens treatments and coating.

Plasma treatment (often mistaken as a lens coating) is a deep-cleaning process that uses oxygen plasma to remove particles from the lens surface—in essence, “super cleaning” the surface of all manufacturing material. The process also ionizes the lens surface molecules to improve hydrophilicity and decrease wetting angles. Unfortunately, the effects are short-lived and can be eliminated through simple lens cleanings.

The newest Food and Drug Administration-approved lens surface coating treatment is Tangible Hydra-PEG (THP). In this process, the lathe cut scleral lens is plasma-treated and then undergoes a secondary process to “grow” a ~40-nanometer film on the lens surface that grants the lens extreme hydrophilicity. In studies evaluating the performance of THP, improvements were observed in subjective comfort, end-of-day comfort, decreased levels of lens deposits, increased tear break-up time on treated lenses, improved subjective visual performance, and increased wear time.¹⁴ See Figure 2.

THE POST LENS TEAR LAYER

Patient complaints of foggy vision may be caused by haptic misalignment. Patients with OSD will frequently produce increased amounts of metabolic and cellular debris (Figure 3).

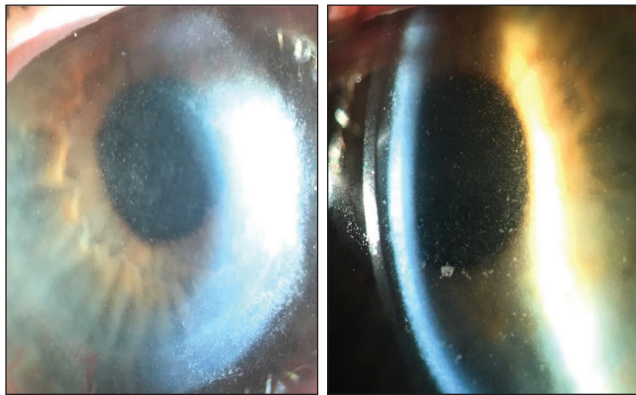


Figure 3. Examples of chamber debris.

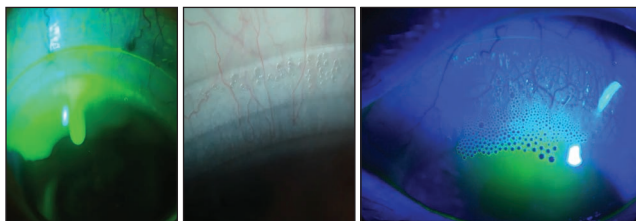


Figure 4. Examples of haptic misalignment.

This debris can enter the PLTL through misalignments in the haptic, and this accumulation of debris may result in reduced visual performance.

There are simple ways to evaluate the scleral lens haptic alignment with a slit lamp. Misalignment will result in “frothing” at the lens edge, patterns of blanching and edge lift, and lens decentration. Fluorescein instillation is one method to evaluate misalignment. In excessive edge lift misalignment, heavy and fast infiltration of fluorescein will present into the PLTL nearly immediately after its insertion. See Figure 4.

After lens removal, uneven conjunctival compression can easily be observed in these cases. Evaluating the pattern of compression, quadrant versus meridian, will aid in identifying appropriate modification to the lens. Also these patients will frequently report lens edge awareness, as the misalignment that allows for tear debris accumulation is excessive edge lift. Many patients can identify the region of awareness, which will correspond with the location of haptic misalignment.

To troubleshoot, simply adjust the haptic alignment. Toric haptics can help minimize chamber debris; when compared to a spherical haptic, the toric produces a curve that allows it to better align to the ocular surface geometry (Figure 5).^{5,7,15,16} Quadrant-specific designs are commercially available as well when the ocular geometry requires. Freeform haptic designs are another option, but are typically available only in computer-aided lens design programs.

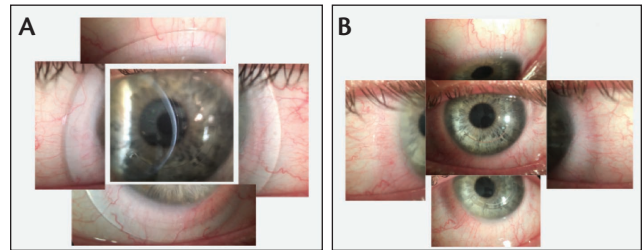


Figure 5. Lens on: note horizontal meridian vessel compression blanching, inferior lens decentration, and superior edge lift—all indicating need for toric haptic (A). Lens off: note horizontal meridian conjunctival tissue compression and absence of tissue compression, superior and inferior (B).

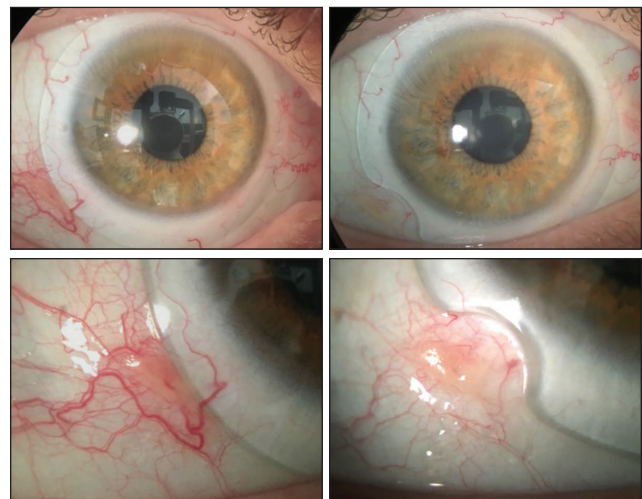


Figure 6. Notch used to relieve focal compression on conjunctival elevation.

Individualized treatment is necessary for patients with unique elevations (such as pinguecula, nodules, and blebs). In these cases, use of lens notching, truncation, or microvaulting circumvent or overcome these elevations (Figure 6). Notches and truncation remove material from the lens haptic to avoid the elevation, whereas microvault technology creates a custom-sized spherical depression in the lens to vault over the elevation, and this can be placed at any point on the lens (Figure 7).

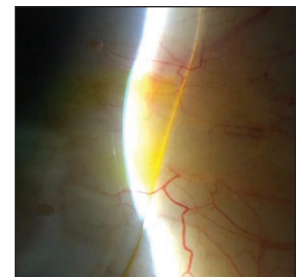


Figure 7. Microvault overlying a pinguecula.

Impression-molded, elevation-specific fitting technology is particularly useful when patients have extremely complex geometry, including severe pinguecula, large nodules, multiple

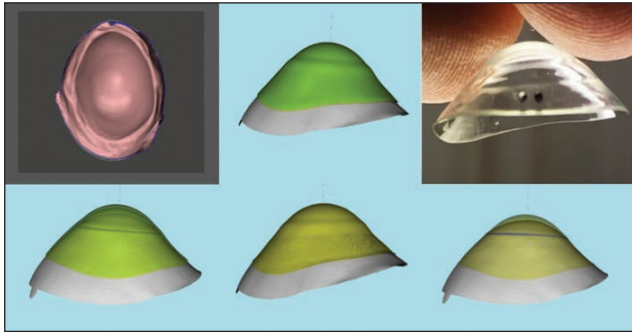
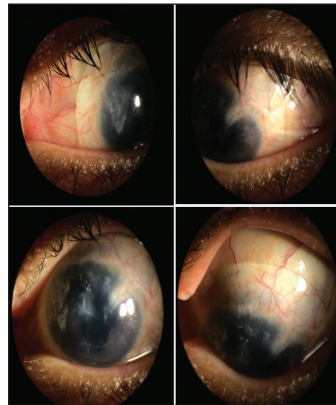


Figure 8. Impression-molded, elevation-specific fitting technology can create lenses for the most geometrically complex cases. This eye had undergone repair after traumatic open globe injury. Multiple lenses were attempted and failed prior to achieving a successful fit using this technology.



blebs, tectonic patch grafts, or post open globe trauma repair irregularity. See Figure 8.

THE CORNEA AND OCULAR SURFACE

In OSD, evaluating the extent to which the ocular surface is affected will help to guide decision-making to choose the correct lens diameter. In cases where the entire ocular surface is affected, the larger the lens, the greater the ocular surface coverage that will make for increased area of protection and healing (Figure 9). If the area needing treatment is contained to the cornea, smaller diameters can be effectively used.

Corneal edema and hypoxic complications are possible in all scleral lens wear, and this may be a direct result of the

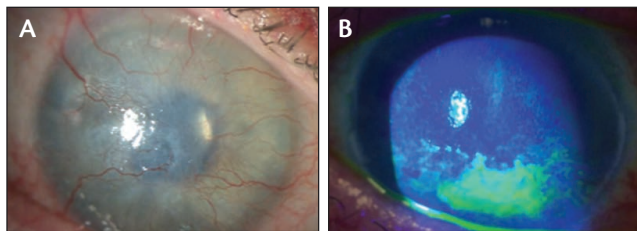


Figure 9. Severe/complex ocular diseases: ocular cicatricial pemphigoid is a panocular surface disease that requires a large diameter to cover and protect the ocular surface (A), in contrast to neurotrophic keratitis, which is contained to the cornea where a smaller diameter is effective (B).

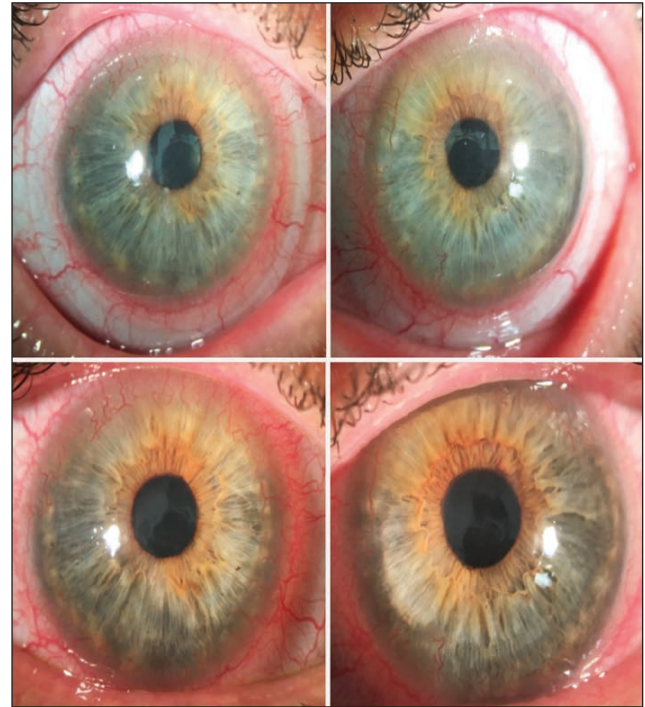


Figure 10. Scleral lens-induced hypoxia.

scleral lens fitting relationships and parameters we chose to use. In our office, we performed a review of more than 40 scleral lens trial fitting sets to aid in defining traditional scleral lens parameters in regards to center thickness, suggested vault, Dk of material, and haptic fitting relationship. We found the following: average lens thickness of ~0.45 mm (ranging .3-.6 mm, greatly dependent on power and base curve), average vaults of 300 μ m (ranged from 100-600 μ m of apical clearance), the average material Dk is 100, and average suggested haptic fitting relationship should show no blanching of the conjunctival vasculature (some stated a quadrant of blanching is acceptable). No guide suggested a fitting relationship that would allow for tear exchange. If the fitting relationship leaves tear exchange absent, then the oxygen received by the cornea is purely what is diffused through the scleral lens system (lens plus PLTL).¹⁷⁻²³

When we consider a scleral lens system with these average values, 450 μ m of lens thickness, 300 μ m of PLTL, the scleral lens system is a 750- μ m barrier between oxygen and the cornea. If the cornea is already diseased or functionally compromised, this may add to the injury.⁷ See Figure 10.

Michaud et al²⁰ developed a simple theoretical formula for calculating the Dk/t of a scleral lens system: $Dk/t=1/[(\text{Thickness of lens}/Dk \text{ of lens material}) + (\text{Thickness of PLTL}/Dk \text{ of Saline}=80)]$. Using that formula and the found averages, the average Dk/t is 12.1; a Dk/t in this range would not be

TABLE. PREDICTED MAXIMAL CENTRAL LENS THICKNESS (M) TO PREVENT HYPOXIA-INDUCED CORNEAL SWELLING IN DAILY LENS WEAR (HM CRITERION) CONSIDERING DETERMINED CLEARANCE VALUES.

	Clearance	100 μm	125 μm	150 μm	200 μm	250 μm	300 μm	350 μm	400 μm
Lens Dk									
100		291	260	229	167	104	42	-20	-80
125		364	325	286	208	130	52	-25	-100
150		437	391	343	250	156	62	-30	-120
170		495	443	389	283	177	70	-35	-136
200		583	521	458	333	208	83	-40	-160
250		729	651	575	417	260	104	-50	-200
300		875	781	687	500	312	125	-60	-240

negative thickness indicates impossibility to manufacture such a lens
 possible to manufacture lens, but it is likely to flex/break because of a reduced thickness
 optimal lenses to manufacture

used on a normal cornea, much less a diseased or functionally compromised cornea (Table).

Michaud et al²⁰ concluded that fitting relationships with scleral lens made to minimize hypoxia-induced corneal swelling need to be made of the highest Dk available (>150), a maximal central thickness of 250 μm , and fitted with a clearance that does not exceed 200 μm .

The literature notes a Dk/t of 24 is necessary to avoid corneal edema for daily wear, and a Dk/t of 35 is necessary to avoid anoxia throughout the entire corneal thickness for open and closed eye conditions for daily wear.^{18,21,22}

The normal physiologic swelling induced by a closed eye during sleep usually recovers within 1 hour of waking. Estimations of swelling induced by scleral lens wear are about 2% to 3% (edema becomes visible at >4%).^{20,24} Unfortunately, patients rarely wait 1 hour after waking before inserting the lens, and most wear their lenses for significantly longer than 12 hours daily. To be without the lens means a return to either poor/nonfunctional vision or a return of the OSD symptoms that the lens relieves. No studies have been published that document the physiologic impact of this constant stress to the cornea over the long term.

Most hypoxic complications that can happen with scleral lenses can be reversed after discontinuation, including endothelial blebs, edema, microcysts, limbal injection, and myopic creep.²⁵ But there are nonreversible complications, including corneal vascularization and endothelial polymegathism and pleomorphism.^{20,24}

There are several simple and prudent ways to increase oxygen to the cornea in scleral lens wear: (1) *Reduce lens thickness* (Figure 11). Utilizing lenses less than 0.25 mm thick reduces the material barrier to oxygen and increases Dk/t. This can be

challenging as this thickness is largely dependent upon the prescription and base curve needed; however, we can use changes to the base curve to offset power of the lens to help control this thickness. (2) *Reduce PLTL thickness (corneal clearance)*. Reducing the clearance as much as possible without touching the cornea. By simply minimizing the PLTL thickness, we are again reducing the barrier to oxygen, and this layer is the lowest Dk (80) in the scleral lens system.

(3) *Use hyper Dk (<120) material*.^{20,24} With a thinner center thickness, there is more possibility of lens flexure but, in my experience, this seldom occurs and can be mitigated with proper lens haptic alignment. With reduced PLTL thickness, we risk more chance for lens touch/bearing after settling (Figure 12). Follow-up with patients at 2 weeks to make gross changes to the lens, then follow-up again after 6 weeks after full settling of the lens has occurred. Only after the lens has settled can clearance be accurately reduced. Try to ensure these patients are seen toward the end of the wear cycle. If an inadequate vault is difficult to view with the lens on, use anterior segment optical coherence tomography for visualization or look for corneal staining with the lens off to determine if more clearance is needed.




Figure 11. Traditional scleral lens (A) vs minimalist scleral lens (B). Note the difference in PLTL and lens thickness.

Finally, fitting relationships on haptics in scleral lenses vary based on practitioner fitting philosophy. I recommend ensuring the haptics are not misaligned, but also that instillation of fluorescein dye is taken up under the lens over a 15-minute period, which will indicate a small amount of tear exchange. Remember, haptics that prove problematic in one patient may not present issues for other patients.²⁶

USING METRICS TO IMPROVE OUTCOMES

Prior to fitting, I collect many corneal metrics and monitor for changes at follow-up. These are valuable for evaluating physiologic response from the cornea to the presence of the scleral lens. The most important metrics are corneal thickness, epithelial thickness, and endothelial cells. It is important that corneal data collected are global data to have a full understanding of impact across the entire tissue (local data can be misleading).

After a patient has been successfully fit with a scleral lens, I recommend follow-up every 3 to 6 months. These are high-needs patients who are well aware of their condition and vision—and they will be the first to note even minor changes in comfort or functional vision. Additionally, these are complex cases, and these patients are also likely to be comanaged so it is important to keep in communication with the other providers.

In summary, scleral lenses used as an adjunctive therapy in OSD are becoming more commonplace. Knowing how to




Figure 12. Corneal bearing after lens settling is unacceptable.

troubleshoot these common issues will aid in patient compliance and recovery. ■

1. Agranat JS, Kitos NR, Jacobs DS. Prosthetic replacement of the ocular surface ecosystem: Impact at 5 years. *Br J Ophthalmol*. 2016;100:1171-1175.
2. DeLoss KS, Le HG, Gire A, et al. PROSE treatment for ocular chronic graft-versus-host disease as a clinical network expands. *Eye Contact Lens*. 2016;42:262-266.
3. Papakostas TD, Le HG, Chodosh J, Jacobs DS. Prosthetic replacement of the ocular surface ecosystem as treatment for ocular surface disease in patients with a history of Stevens-Johnson syndrome/toxic epidermal necrolysis. *Ophthalmology*. 2015;122:248-253.
4. Schormack MM. Limbal stem cell disease: Management with scleral lenses. *Clin Exp Optom*. 2011;94:592-594.
5. Schormack MM. Scleral lenses: A literature review. *Eye Contact Lens*. 2015;41:3-11.
6. Schormack MM, Baratz KH. Ocular cicatricial pemphigoid: The role of scleral lenses in disease management. *Cornea*. 2009;28:1170-1172.
7. Schormack MM, Pyle J, Patel SV. Scleral lenses in the management of ocular surface disease. *Ophthalmology*. 2014;121:1398-1405.
8. Gire A, Kwok A, Marx DP. PROSE treatment for lagophthalmos and exposure keratopathy. *Ophthalm Plast Reconstr Surg*. 2013;29:e38-40.
9. Dimit R, Gire A, Pflugfelder SC, Bergmanson JP. Patient ocular conditions and clinical outcomes using a PROSE scleral device. *Cont Lens Anterior Eye*. 2013;36:159-163.
10. Rosenthal P, Croteau A. Fluid-ventilated, gas-permeable scleral contact lens is an effective option for managing severe ocular surface disease and many corneal disorders that would otherwise require penetrating keratoplasty. *Eye Contact Lens*. 2005;31:130-134.
11. Takahide K, Parker PM, Wu M, et al. Use of fluid-ventilated, gas-permeable scleral lens for management of severe keratoconjunctivitis sicca secondary to chronic graft-versus-host disease. *Biol Blood Marrow Transplant*. 2007;13:1016-1021.
12. Visser ES, Soeters N, Tahzib NG. Scleral lens tolerance after corneal cross-linking for keratoconus. *Optom Vis Sci*. 2015;92:318-323.
13. Visser ES, Wisse RP, Soeters N, et al. Objective and subjective evaluation of the performance of medical contact lenses fitted using a contact lens selection algorithm. *Cont Lens Anterior Eye*. 2016;39:298-306.
14. Sindt CW. Tangible Hydra-PEG: A novel custom contact lens coating technology designed to improve patient comfort and satisfaction. https://www.artoptical.com/storage/docs/THP_White_Paper.pdf. Published 2016. Accessed March 22, 2017.
15. Visser ES, Van der Linden BJ, Otten HM, et al. Medical applications and outcomes of bitangential scleral lenses. *Optom Vis Sci*. 2013;90:1078-1085.
16. Visser ES, Visser R, Van Lier HJ. Advantages of toric scleral lenses. *Optom Vis Sci*. 2006;83:233-236.
17. Morgan PB, Brennan NA, Maldonado-Codina C, et al. Central and peripheral oxygen transmissibility thresholds to avoid corneal swelling during open eye soft contact lens wear. *J Biomed Mater Res B Appl Biomater*. 2010;92:361-365.
18. Holden BA, Mertz GW. Critical oxygen levels to avoid corneal edema for daily and extended wear contact lenses. *Invest Ophthalmol Vis Sci*. 1984;25:1161-1167.
19. Brennan NA. Corneal oxygenation during contact lens wear: Comparison of diffusion and EOP-based flux models. *Clin Exp Optom*. 2005;88:103-108.
20. Michaud L, van der Worp E, Brazeau D, et al. Predicting estimates of oxygen transmissibility for scleral lenses. *Cont Lens Anterior Eye*. 2012;35:266-271.
21. Papas E. On the relationship between soft contact lens oxygen transmissibility and induced limbal hyperaemia. *Exp Eye Res*. 1998;67:125-131.
22. Harvitt DM, Bonanno JA. Re-evaluation of the oxygen diffusion model for predicting minimum contact lens Dk/t values needed to avoid corneal anoxia. *Optom Vis Sci*. 1999;76:712-719.
23. Sweeney DF. Have silicone hydrogel lenses eliminated hypoxia? *Eye Contact Lens*. 2013;39:53-60.
24. Michaud L. Scleral lens fitting: Once rare, now routine? <https://www.reviewofoptometry.com/ce/scleral-lens-fitting-once-rare>. Published April 2016. Accessed January 31, 2017.
25. Vincent SJ, Alonso-Caneiro D, Collins MJ, et al. Hypoxic corneal changes following eight hours of scleral contact lens wear. *Optom Vis Sci*. 2016;93:293-299.
26. Walker MK, Bergmanson JP, Miller WL, et al. Complications and fitting challenges associated with scleral contact lenses: A review. *Cont Lens Anterior Eye*. 2016;39:88-96.

The Magic of MIGS

Because of the increasing number of glaucoma patients, our clinics will see an increasing number of patients with MIGS devices.

By Justin Schweitzer, OD, FAAO, and Brett King, OD, FAAO

Most patients are nonadherent to their ocular medication dosing regimens, and nearly 50% discontinue taking their medications within the first 6 months.¹ In the recent past, we would manage our glaucoma patients by adding glaucoma medication on top of glaucoma medication—sometimes up to three daily. If that was unsuccessful at controlling their glaucoma, we might send the patient to a surgeon for selective laser trabeculoplasty. If they still progressed, back to the surgeon the patient would go, this time for a much more invasive filtration surgery, which comes with well-known complications and failure rates.²⁻⁶

Thankfully, the advent of microinvasive glaucoma surgery (MIGS) has helped alter the landscape for our glaucoma patients. MIGS will not likely eliminate topical medications completely, but it may help significantly reduce the number of drops needed to maintain proper IOP control. There are already several MIGS devices, tools, and procedures approved in the United States, including the iStent, the CyPass Micro-Stent, the Xen45, the Trabectome, the Kahook Dual Blade, and endoscopic cyclophotocoagulation (ECP). In the pipeline are the Hydrus Microstent, and the iStent Inject and iStent Supra. The iStent and CyPass are approved for use in concurrent cataract surgery, but are also being investigated as standalone procedures.

For optometrists, follow-up with these patients will necessitate being comfortable with the angle anatomy and gonioscopy skills. This will allow optometrists to easily identify the devices and recognize some of the postoperative complications that MIGS devices may create. Because of the increasing number of glaucoma patients, our clinics will see an increasing number of patients with MIGS devices.

DEVICES

In 2012, the iStent was approved by the Food and Drug Administration (FDA) for use in conjunction with cataract surgery. It is the smallest FDA-approved medical device known to be implanted in the human body.^{4,7-9} The stent is small enough to fit in the ridge of a fingerprint. The stent creates a permanent patent bypass through the trabecular meshwork and into Schlemm canal to facilitate physiological outflow and, thus, lower IOP. The implantation of the iStent at the same time as cataract surgery has a better safety profile compared with traditional filtration surgeries in combination with cataract surgery.¹⁰⁻¹²

The CyPass stent is a small, fenestrated, polyamide device that was recently approved by the FDA.¹³ The device is placed in the supraciliary space to maximize use of uveoscleral outflow and avoids the trabecular meshwork and Schlemm canal.¹⁴ The device targets the suprachoroidal space, which has a larger absorptive capacity, allowing increased outflow and IOP lowering compared with the trabecular pathway. In essence, it is a controlled iridodialysis.

The Xen45 implant is the latest to achieve US regulatory approval.¹⁵ It uses an ab interno subconjunctival approach to lowering IOP. The Xen45 is a soft, flexible gelatin implant about the diameter of a human hair. It shunts fluid from the anterior chamber to the subconjunctival space. This stent is different from others in that it bypasses the natural drainage pathway and can produce the lower IOPs that typically are achieved only with a trabeculectomy or tube shunt. The implant procedure can be done alone or as part of cataract surgery. In a recent study the unmedicated mean IOP decreased from 25.1 mm Hg to 15.9 mm Hg at 12 months.¹⁵ Results also indicate the mean number of medications decreased from 3.5 at baseline to 1.7 at 12 months.¹⁵

INVESTIGATIONAL DEVICES

The Hydrus Microstent is about the size of an eyelash and is placed inside Schlemm canal through a clear corneal incision during cataract surgery. It increases outflow by acting as a scaffold and dilating Schlemm canal over 3 clock hours, allowing aqueous to bypass the trabecular meshwork and provide direct aqueous access to multiple collector channels. At 24 months, 80% of the Hydrus subjects achieved a 20% reduction in washed out diurnal IOP compared to only 20% in the cataract surgery-only group.¹⁶ Plus, 73% of the Hydrus patients were not taking any hypotensive medications, compared to 38% in the cataract surgery-only group.¹⁶ The mean number of medications after Hydrus was 0.8, down from about 2.5 medications.¹³

The iStent inject is a second-generation version of the iStent. The device resembles a rivet or punctal plug. The surgeon injects it through trabecular meshwork into Schlemm canal and more than one of the devices can be implanted. The head resides in the anterior chamber, aqueous will pass through the lumen, and exit the end of the device residing in Schlemm canal. Two versions are currently in development: one for use in conjunction with cataract surgery and one for use as a standalone procedure.

Unpublished data (n=57) shows a mean IOP at month 18 ranging from 13.6 to 14.6 mm Hg (down from an unmedicated baseline of 24.4 mm Hg) and no medication use.¹⁷

The iStent Supra device, similar to CyPass, is designed to shunt aqueous through the uveoscleral outflow pathway. The stent is a 4-mm tube made of polyethersulfone and titanium and is designed to be placed in the supraciliary space. Already approved in the European Union, this device is in clinical studies in the United States. The 12-month data in patients previously uncontrolled on two topical medications found the device to be safe and able to substantially reduce IOP.¹⁸

OTHER TOOLS AND DEVICES

The Kahook Dual Blade has a tapered tip designed to be eased into Schlemm canal, after which the device slides along the trabecular meshwork. The blade that is in the canal lifts and stretches the trabecular meshwork so that the second blade can safely cut the tissue. This allows for cleaner tissue removal and minimizes damage to adjacent tissue.⁹

The Trabectome is a handheld instrument that uses microelectrocautery to ablate a 60° to 120° strip of trabecular meshwork and the inner wall of Schlemm canal. Irrigation and aspiration is simultaneously performed to remove ablated tissue. The ablation allows aqueous to have direct access to the outflow collector channels of Schlemm canal, thereby lowering IOP.

There is ongoing debate about which is a better process—stripping the wound or ablating the tissue, but no consensus has been reached.

POSTOPERATIVE CONSIDERATIONS

There are a few postoperative considerations optometrists will be faced with when managing patients that have had MIGS procedures. These include IOP spikes, microhyphema, and IOP fluctuations.

We recommend explaining to patients that in the short term postoperatively, their IOP is going to fluctuate—avoid overselling these procedures and devices by promising low IOP during that early postoperative period. For that reason, we also avoid making any decisions about glaucoma medications until the new baseline IOP has been established. This, at times, can take up to 3 months and these patients will need frequent monitoring during that time. IOP spikes are a consideration with any type of intraocular surgery, but are more of a concern when dealing with patients with compromised optic nerve heads. Topical glaucoma medications can be used to manage IOP spikes in the early postoperative period, but another option is to consider a quick anterior chamber decompression or burping of the wound. A sterile punctal dilator works well to perform this procedure. A small amount of pressure is placed

on the outside edge of the paracentesis wound and a small amount of aqueous humor is released. A drop of antibiotic is instilled after the procedure is complete. It is a quick and safe way to lower the IOP for someone who has had a pressure spike. Caution is advised to monitor the amount of fluid being released so that the IOP does not drop too low and increase the risk of a decompression retinopathy.

Another postoperative consideration is microhyphema, and managing patient expectations preoperatively is crucial here. Patients who experience microhyphema postoperatively are likely to have slightly blurry or cloudy vision for a week or so, and then it will clear. Reminding the patient during the immediate postoperative period that this can happen should help reduce patient anxiety.

A final but uncommon postoperative finding is an occluded stent typically by a tuft of iris tissue. The use of a YAG laser can be used to open the stent and make it functional again.

CONCLUSION

In short, MIGS devices have been shown to be safe and efficacious with similar recovery as cataract surgery. For those patients who need more IOP control than cataract surgery alone can provide, MIGS is a viable option, and we are likely to see more and more patients with these devices in the near future. ■

1. Nordstrom BL, Friedman DS, Mozaffari E, et al. Persistence and adherence with topical glaucoma therapy. *Am J Ophthalmol*. 2005;140(4):598-606.
2. Abdelrahman AM. Noninvasive glaucoma procedures: current options and future innovations. *Middle East Afr J Ophthalmol*. 2015;22(1):2-9.
3. Fea A, Cannizzo PM, Consolandi G, et al. Managing drawbacks in unconventional successful glaucoma surgery: A case report of stent exposure. *Case Rep Ophthalmol Med*. 2015;2015:847439.
4. Razeghinejad MR, Spaeth GL. A history of the surgical management of glaucoma. *Optom Vis Sci*. 2011;88(1):E39-47.
5. SooHoo JR, Seibold LK, Radcliffe NM, Kahook MY. Minimally invasive glaucoma surgery: Current implants and future innovations. *Can J Ophthalmol*. 2014;49(6):528-533.
6. Taubenslag KJ, Kammer JA. Outcomes disparities between black and white populations in the surgical management of glaucoma. *Semin Ophthalmol*. 2016;31(4):385-393.
7. Resende AF, Patel NS, Waisbourd M, Katz LJ. iStent trabecular microbypass stent: An update. *J Ophthalmol*. 2016;2016:2731856.
8. Richter GM, Coleman AL. Minimally invasive glaucoma surgery: Current status and future prospects. *Clin Ophthalmol*. 2016;10:189-206.
9. Saheb H, Ahmed, II. Micro-invasive glaucoma surgery: Current perspectives and future directions. *Curr Opin Ophthalmol*. 2012;23(2):96-104.
10. Samuelson TW, Katz LJ, Wells JM, et al. Randomized evaluation of the trabecular micro-bypass stent with phacoemulsification in patients with glaucoma and cataract. *Ophthalmology*. 2011;118(3):459-467.
11. DeBry PW, Perkins TW, Heatley G, et al. Incidence of late-onset bleb-related complications following trabeculectomy with mitomycin. *Arch Ophthalmol*. 2002;120(3):297-300.
12. Edmunds B, Thompson JR, Salmon JF, Wormald RP. The National Survey of Trabeculectomy. III. Early and late complications. *Eye (Lond)*. 2002;16(3):297-303.
13. Novartis. Alcon achieves US approval for CyPass Micro-Stent, a micro invasive surgical device to treat glaucoma. <https://www.novartis.com/news/media-releases/alcon-achieves-us-approval-cypass-micro-stent-micro-invasive-surgical-device>. Published August 2, 2016. Accessed January 17, 2017.
14. Vold S, Ahmed, II, Craven ER, et al. Two-year COMPASS trial results: Supraciliary microstenting with phacoemulsification in patients with open-angle glaucoma and cataracts. *Ophthalmology*. 2016;123(10):2103-2112.
15. Allergan. Allergan receives FDA clearance for the XEN Gel Stent, a new surgical treatment for refractory glaucoma. <https://www.allergan.com/news/news/thomson-reuters/allergan-receives-fda-clearance-for-the-xen-gel-st>. Published November 22, 2016. Accessed January 18, 2017.
16. Pfeiffer N, Garcia-Feijoo J, Martinez-de-la-Casa JM, et al. A randomized trial of a Schlemm's canal microstent with phacoemulsification for reducing intraocular pressure in open-angle glaucoma. *Ophthalmology*. 2015;122(7):1283-1293.
17. Lindstrom RL. Use of second generation trabecular stents as sole procedure in eyes with open-angle glaucoma on 1 preoperative medication: 18-month report. Presented at: American Society of Cataract and Refractive Surgery annual meeting; May 6-10, 2016; New Orleans, LA.
18. Kammer JA, Mundy KM. Suprachoroidal devices in glaucoma surgery. *Middle East Afr J Ophthalmol*. 2015;22(1):45-52.

Modern Cataract Surgery and Where We are Heading

It is important to educate patients about IOL options.

By Josh Johnston, OD, FFAO

Optometrists are often the first eye care professionals patients visit and, as such, tend to be the gatekeepers for cataract referrals.¹ Part of our responsibility is to educate patients about IOL options. Cataract surgery is now refractive surgery, with patient expectations increasingly demanding. These are patients who now expect plano results even with traditional monofocal IOLs and good vision at all distances and minimal reliance upon spectacles with advanced technology IOLs. It is a challenge, but there are newer technologies available that can deliver on those promises.

AcrySof toric and Tecnis toric IOLs can treat up to 6.00 D of corneal astigmatism (which provides about 4.00 D of treatment, according to their respective companies). Most of the population has corneal astigmatism that can be corrected with an IOL, but substantially fewer patients receive a toric lens. We need to do a better job of educating our patients about this technology.

These are easy subjects to discuss with our patients—they already understand what astigmatism is and why they need different types of spectacle or contact lens correction than someone without astigmatism. Likewise, these patients also understand presbyopia and are easily educated about multifocal lenses. Trulign was the first toric accommodating IOL approved in the United States, and provides a treatment range of 1.25 to 2.75 D of corneal cylinder.

Extended depth of focus (EDoF) is the newest category of IOLs. It uses diffractive optics that provide a continuous range of vision across all distances, and in some patients decreases the neuroadaptation time needed compared to other multifocal IOLs.²

When multifocal lenses were first introduced, ophthalmologists would “mix and match” but that lost favor after a few years. There are now lower-add multifocal lenses, such as the ReSTOR +2.5 apodized diffractive multifocal IOL that splits light into distance and near (+2.5 add) foci. In this lens, there is less light lost compared to roughly 18% loss of light that hits the retina with the original higher-add power IOL.³ The amount of light committed to the near or distance foci is pupil-dependent. The newest Tecnis multifocal aspheric diffractive lens is similar to the AcrySof, with the lower-add power IOLs having fewer diffractive rings, which helps decrease glare and halo.⁴ These lenses are for people with distance and intermediate-dominant lifestyles, and they still get good near vision. The merging of cataract and refractive surgery is exemplified by the newly FDA-approved AcrySof

ReSTOR multifocal toric lens. This IOL can treat up to 2.50 D of astigmatism and provides diffractive multifocality. There may be greater use of this lens among “nonrefractive” surgeons because it provides options for those with greater amounts of astigmatism without needing to bring the patient back for follow-up procedures, such as limbal relaxing incisions, PRK, and LASIK. Less chair time for one patient equates to more patients being treated overall. When we are discussing these lenses with patients, it is imperative that we set realistic expectations and discuss the potential for developing glare and halo.

FUTURE IOL DESIGNS

Several IOLs have received the CE Mark in Europe, including various EDoF IOLs and trifocal IOLs. The AcuFocus IC-8 is a small aperture EDoF IOL designed to improve visual quality across a broad range for patients with presbyopia who undergo either refractive lens exchange or cataract surgery. The pinhole effect provides the range of vision so one eye provides intermediate and near vision and the dominant distance eye receives a monofocal lens.

The Tecnis Symphony is the only EDoF IOL with US regulatory approval. It is similar in look to a multifocal lens, but it is not considered a multifocal. According to the company who makes them, the lens has a proprietary diffractive echelette design that extends the range of vision; its proprietary achromatic technology corrects chromatic aberration for enhanced contrast sensitivity. They note that contrast sensitivity performance is comparable to its one-piece monofocal IOLs.²

Trifocal lenses use a first and second order add diffractive grating to provide an improvement in intermediate vision while still producing excellent near and distance outcomes. The FineVision trifocal IOL has achieved a CE Mark in Europe, as well the AcrySof IQ PanOptix trifocal lens, which provides comfortable near to intermediate vision (40-80 cm) with a focal point at 60 cm.

Other lenses are still awaiting a CE Mark, including the FluidVision accommodating IOL, the Lumina, Dynacurve, and Light Adjustable Lens.

The FluidVision uses soft haptics to store silicone fluid; in accommodation the fluid is forced into a central optic and produces a power change by fluid movement between the haptics and optic. Nonpublished data suggests the lens may be able to provide up to 5.00 to 10.00 D of accommodation.

The promise of the Light Adjustable Lens is that it can provide predictable correction of residual refractive error after lens implantation to ensure optimal distance vision, and can correct spherical and cylindrical errors up to 2.00 D. The developers note the lens can provide customized presbyopia solutions for both near and intermediate vision by adjusting the monovision, customizing a near add, and through asphericity control.

As these newer technologies come to market, we as optometrists will be charged with understanding the technologies so that we can provide better postoperative care. The incoming Baby

Boomer generation will drive the premium IOL market as they did with LASIK. We will be charged with educating this group of patients about potential benefits, but also what the compromise may be with any particular lens. ■

1. Murrill CA, Stanfield DL, VanBrocklin MD; American Optometric Association Consensus Panel. Care of the adult patient with cataract. <http://www.aoa.org/documents/optometrists/CPG-8.pdf>. Published June 28, 1995. Accessed March 14, 2017.
2. TECNIS Symfony Extended Range of Vision IOLs DFU. Santa Ana, CA, Abbott Medical Optics Inc. <https://www.vision.abbott/us/iols/extended-depth-of-focus/tecnis-symfony.html>. Accessed March 21, 2017.
3. Vryghem JC, Heireman S. Visual performance after the implantation of a new trifocal intraocular lens. *Clin Ophthalmol*. 2013;7:1957-1965.
4. TECNIS Multifocal 1-Piece IOL DFU, Models ZKB00 and ZLB00. Santa Ana, CA, Abbott Medical Optics Inc. <https://www.vision.abbott/us/iols/multifocal/tecnis-multifocal-275d.html>. Accessed March 21, 2017.

Bugs & Drugs: Battling Bacterial Keratitis

Technologies emerging for the treatment and management of keratitis are continually evolving and improving our ability to treat patients more rapidly and safely.

By Scott G. Hauswirth, OD, FAAO, and Nate Lighthizer, OD, FAAO

The overwhelming majority of keratitis visits to eye care practitioners (76.5%) result in antimicrobial prescriptions.¹ Worldwide, bacterial infections are still predominant and are found in 80% of patients with ulcerative keratitis.² In the United States, about 30,000 cases of infectious keratitis are reported yearly.³ Worldwide, there are approximately 1.5 million cases yearly.⁴ That makes infectious keratitis one of the leading causes of corneal blindness worldwide. The at-risk population includes contact lens wearers, with overnight contact lens use the leading risk factor; this group comprise a much higher risk factor than the average patient.⁵

Second, people with comorbid ocular surface pathology, including dry eye, are also at risk. The third leading risk factor is ocular injury/trauma that can be surgical, from a fingernail, or a foreign body.^{6,7}

Other at-risk populations include immunocompromised individuals, those who frequently use ocular medications, and those with poor lid mechanics/exposure.⁶

During the examination, being as detailed as possible with a case history is necessary to help determine when the infection began, and may identify clues to help determine what kind of bacteria may be causing the infection. When possible, document as specifically as possible (within 1/10th of a millimeter) the size of the epi-defect, whether there is any excavation present, detailing the size of the infiltrate and its appearance, its density, and include a description of satellite lesions, if present.

Incorporating culturing into a primary OD practice is becoming more common. We recommend culturing when the defect is central, had a rapid onset (within 24-48 hours

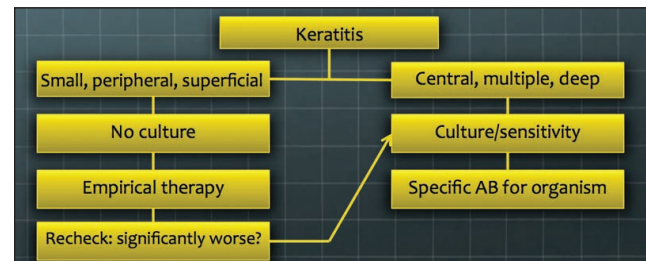


Figure 1. When to culture.

of presentation), is large (>3mm), or is nonresponsive to initial treatment. See Figure 1 for a decision tree algorithm.⁸

HOW TO CULTURE

The standard method for culturing involves scraping the lesion either with a swab or a spatula; our preference is calcium alginate swabs, which have a fairly small tip as opposed to a standard cotton swab. In our hands, we can use those swabs to dig into the lesion, enabling us to potentially get a higher rate of bacterial accumulation at the end of the tip so plating is more likely to be successful.

Traditional culturing includes using a variety of medium—the primary medium used for aerobic bacteria are blood and chocolate plates, and thioglycate broth. Other media can be used to look for anaerobic bacteria, atypical mycobacteria, fungus or yeast, and even virus.

There has been an increasing trend toward the use of e-swabs. This has simplified the process for practitioners in that we can now culture several types of bacteria with a single medium. They overcome several disadvantages of plating, including

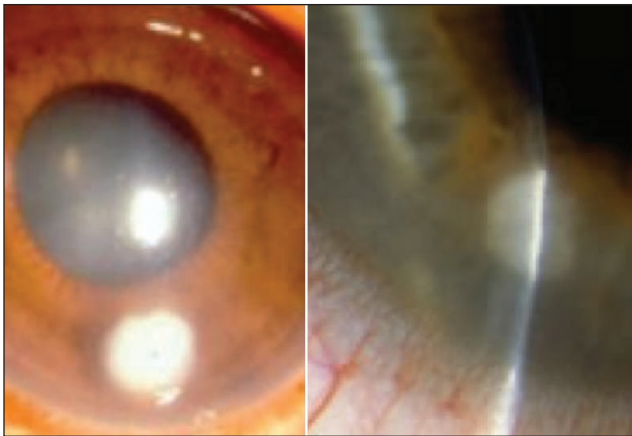


Figure 2. Examples of *Staphylococcus aureus*.

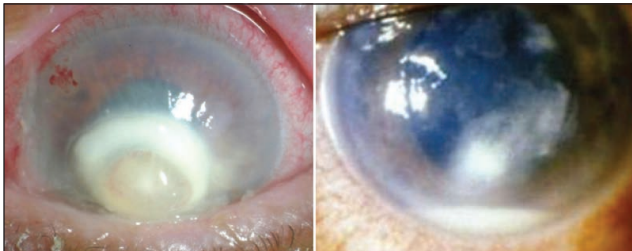


Figure 3. Examples of *Streptococcus pneumoniae*.

being able to be stored at room temperature for short periods of time, avoiding the condensation plates develop from being stored upside down, and being less sensitive to temperature fluctuations. However, they are also unable to capture several classes of bacteria, including atypical mycobacteria.

BACTERIAL IDENTIFICATION

There are two primary types of bacteria that we encounter most frequently—Gram-positive and Gram-negative. Gram-positive organisms account for 50% to 90% of all keratitis cases seen in the United States.⁹⁻¹¹ *Staphylococcus* is the most frequently isolated organism from bacterial keratitis.⁸ Insurance data showed the most common cause of bacterial keratitis is *S. aureus*.¹² *S. aureus* are typically round lesions, with more focal infiltrates with distinct edges. Methicillin-resistant *S. aureus* (MRSA) is the most common post-LASIK infection in the United States.¹³ MRSA has been found responsible for 52.8% of keratitis infections in one Taiwanese hospital.¹⁴

In Figure 2, the overlying epi-defect is typically just a little bit less than the size of the infiltrate. These tend to worsen over the course of about 2 or maybe 3 days.

Conversely, *Streptococcus pneumoniae* is a much more aggressive organism that tends to evolve at a faster pace. Like Staph infections, Strep infections typically are very dense, with

very focal white infiltrates, but which may become severe within 1 or 2 days from onset. It is difficult to see much in the iris detail through the lesion. *S. pneumoniae* occurs deeper and tends to also be associated with a higher likelihood of anterior chamber reaction. As Figure 3 illustrates, it is not unusual for hypopyon to be present in patients with Strep infections.

Several classes of drugs are available to treat Gram-positive infections, including macrolides, fluoroquinolones, and glycopeptides. These days, we tend to prescribe chlorinated fluoroquinolones, such as besifloxacin, which has demonstrated good efficacy against Gram-positive organisms, including MRSA.¹⁵ The fourth-generation fluoroquinolones remain a viable and trusted option. Besifloxacin is commercially available and highly recommended because it does not need to be compounded.¹⁶ Polytrim and tobramycin are also used, but tobramycin is the least effective of these options.

MRSA outbreaks are increasing in all presentations, so whether you are treating a conjunctivitis, cellulitis, or keratitis, keep the possibility of MRSA in mind.

Trust in the Rule of 1-2-3: For any lesion that is within 1 mm of the visual axis, if the eye has 2 or more lesions, or if the lesion is 3 mm in size or larger, the use of fortified antibiotics or prescribing two different antibiotics is recommended.

The Ocular Trust 3 and ARMOR studies¹⁷⁻¹⁹ showed us that many antimicrobials work on typical non-MRSA Staph infections. However, those same studies showed that fewer than one-third of fluoroquinolones work against MRSA, with the exception of trimethoprim and tobramycin.¹⁷⁻¹⁹ The susceptibility profiles remain virtually identical for the fluoroquinolones, regardless of methicillin phenotype. *S. aureus* is more susceptible to the fluoroquinolones than to macrolides.

For suspected ocular MRSA infection, vancomycin still remains the standard treatment, although it will need to be compounded for use in ocular formulation. If there is a strong suspicion of MRSA, or if the patient has been minimally responsive to general fluoroquinolone therapy, then we typically will prescribe vancomycin.

Gram-negative infections are distinct, and account for 10% to 50% of keratitis in the United States.^{10,20} The most common of these infections is *Pseudomonas aeruginosa*: in a study of 1,317 patients with culture-confirmed conjunctivitis, 0.7% were *P. aeruginosa*.¹⁶ The characteristics of Gram-negative infections include a very rapid onset and progression, and may affect the majority of the cornea within a day of initial onset; there can be marked purulence; a necrosed appearance to epithelium; a deep stromal infiltrate, which may progress to a ring; grayish appearance; and a marked anterior chamber reaction or hypopyon.

These infections are more difficult to treat, and may even perforate within 24 to 36 hours of onset.²¹ The faster the

infection can be recognized and classified, the better the potential outcome for the patient.

There are two main classes of medications used to treat Gram-negative infections: aminoglycosides and fluoroquinolones. We primarily use fortified tobramycin (compounded). Besifloxacin has also demonstrated efficacy against *Pseudomonas*.¹⁶ Oral doxycycline and tetracycline can be useful in more aggressive, necrotic ulcers and are typically adjunctive therapies.²¹ Animal studies suggest they help speed re-epithelialization through matrix metalloproteinase 9 inhibition and may protect the stroma against necrosis by inhibiting collagenase activity.

The SCUT study²² helped define when steroids are appropriate: results showed that adjunctive topical steroids did not improve 3-month vision in patients with bacterial corneal ulcers. However, topical steroid treatment did improve visual acuity in patients with the worst visual acuity and central ulcer location at baseline. Individualized treatment is necessary, and clinicians need to weigh the risk-to-benefit of adding steroids into their treatment. Generally speaking, steroids are generally not recommended for infectious bacterial corneal ulcers until clinical improvement is noticed with antibiotics alone.

AMNIOTIC MEMBRANE AND CROSSLINKING

Amniotic membrane can help with re-epithelialization and sequestration of white blood cells, which reduces inflammation and scarring,²³ but there are only a few small studies in the literature that analyze amniotic membrane in infectious keratitis. Sheha et al reported on a small case series (n=3), in which amniotic membrane seemed efficacious.²³ This technology may be considered in lieu of a steroid.

Corneal collagen crosslinking for bacterial keratitis may be helpful as well. These cases typically use the epithelium-off method. A patient who presented with a painful peripheral corneal infiltrate underwent PACK-crosslinking with a local limited abrasion and accelerated ultraviolet-A irradiation at 365 nm and 9 mW/cm² for 10 minutes; PACK-crosslinking was successfully used as a first-line and sole treatment.²⁴ A meta-analysis of outcomes found an 85.8% success rate against bacterial infections and a 78% success rate against fungal infections.²⁵

CONCLUSION

It is important to recognize that both contact lens wearers and people with dry eye are at a higher risk for bacterial

infections, and these are likely a majority of the patients in our practices. As a first-line treatment, chlorinated fluoroquinolones are our primary choice when it comes to treating corneal infections. Optometric practices can now incorporate corneal culturing—which may be achieved more easily with e-swabs—that can lead to more rapid identification of the organism and treatment more suited to that particular infection. Finally, technologies emerging for the treatment and management of keratitis are continually evolving and improving our ability to treat patients more rapidly and safely. ■

- Collier SA, Gronostaj MP, MacGurn AK, et al. Estimated burden of keratitis—United States, 2010. *MMWR Morb Mortal Wkly Rep*. 2014;63(45):1027–1030.
- Rachwalik D, Pleyer U. Bacterial Keratitis. *Klin Monbl Augenheilkd*. 2015;232(6):738–744.
- PePOSE JS, Wilhelmus KR. Divergent approaches to the management of corneal ulcers. *Am J Ophthalmol*. 1992;114(5):630–632.
- Whitcher JP, Srinivasan M, Upadhyay MP. Corneal blindness: A global perspective. *Bull World Health Organ*. 2001;79(3):214–221.
- Keay L, Stapleton F. Development and evaluation of evidence-based guidelines on contact lens-related microbial keratitis. *Cont Lens Anterior Eye*. 2008;31(1):3–12.
- Aldebasi YH, Aly SM, Ahmad MI, Khan AA. Incidence and risk factors of bacteria causing infectious keratitis. *Saudi Med J*. 2013;34(11):1156–1160.
- Ng AL, To KK, Choi CC, et al. Predisposing factors, microbial characteristics, and clinical outcome of microbial keratitis in a tertiary centre in Hong Kong: A 10-year experience. *J Ophthalmol*. 2015;2015:769436.
- American Academy of Ophthalmology Cornea/External Disease Panel. Bacterial keratitis. <https://www.aao.org/preferred-practice-pattern/bacterial-keratitis-ppp--2013>. Published October 2013. Accessed: March 14, 2017.
- Lin TY, Yeh LK, Ma DH, et al. Risk factors and microbiological features of patients hospitalized for microbial keratitis: A 10-year study in a referral center in Taiwan. *Medicine (Baltimore)*. 2015;94(43):e1905.
- Sand D, She R, Shulman IA, et al. Microbial keratitis in Los Angeles: The Doheny Eye Institute and the Los Angeles County hospital experience. *Ophthalmology*. 2015;122(5):918–924.
- Gopinathan U, Sharma S, Garg P, Rao GN. Review of epidemiological features, microbiological diagnosis and treatment outcome of microbial keratitis: Experience of over a decade. *Indian J Ophthalmol*. 2009;57(4):273–279.
- Jeng BH, Gritz DC, Kumar AB, et al. Epidemiology of ulcerative keratitis in Northern California. *Arch Ophthalmol*. 2010;128(8):1022–1028.
- Mah FS, Davidson R, Holland EJ, et al. Current knowledge about and recommendations for ocular methicillin-resistant *Staphylococcus aureus*. *J Cataract Refract Surg*. 2014;40(11):1894–1908.
- Hsiao CH, Chuang CC, Tan HY, et al. Methicillin-resistant *Staphylococcus aureus* ocular infection: A 10-year hospital-based study. *Ophthalmology*. 2012;119(3):522–527.
- Mah FS, Sanfilippo CM. Besifloxacin: Efficacy and safety in treatment and prevention of ocular bacterial infections. *Ophthalmol Ther*. 2016;5(1):1–20.
- Silverstein BE, Morris TW, Gearinger LS, et al. Besifloxacin ophthalmic suspension 0.6% in the treatment of bacterial conjunctivitis patients with *Pseudomonas aeruginosa* infections. *Clin Ophthalmol*. 2012;6:1987–1996.
- Asbell PA, Sahm, DF, Shedden, A. Ocular TRUST 3: Ongoing longitudinal surveillance of antimicrobial susceptibility in ocular isolates. Presented at: American Society of Cataract and Refractive Surgery Annual Meeting; April 7, 2009; San Francisco, CA.
- Asbell PA, Colby KA, Deng S, et al. Ocular TRUST: Nationwide antimicrobial susceptibility patterns in ocular isolates. *Am J Ophthalmol*. 2008;145(6):951–958.
- Asbell PA, Sanfilippo CM, Pillar CM, et al. Antibiotic resistance among ocular pathogens in the United States: Five-year results from the antibiotic resistance monitoring in ocular microorganisms (ARMOR) surveillance study. *JAMA Ophthalmol*. 2015;133(12):1445–1454.
- Prokosch V, Gatzoufias Z, Thanos S, Stupp T. Microbiological findings and predisposing risk factors in corneal ulcers. *Graefes Arch Clin Exp Ophthalmol*. 2012;250(3):369–374.
- McElvanney AM. Doxycycline in the management of pseudomonas corneal melting: Two case reports and a review of the literature. *Eye Contact Lens*. 2003;29(4):258–261.
- Srinivasan M, Mascarenhas J, Rajaraman R, et al. Corticosteroids for bacterial keratitis: The steroids for corneal ulcers trial (SCUT). *Arch Ophthalmol*. 2012;130(2):143–150.
- Sheha H, Liang L, Li J, Tseng SC. Sutureless amniotic membrane transplantation for severe bacterial keratitis. *Cornea*. 2009;28(10):1118–1123.
- Tabibian D, Richo O, Riat A, et al. Accelerated photoactivated chromophore for keratitis-corneal collagen cross-linking as a first-line and sole treatment in early fungal keratitis. *J Refract Surg*. 2014;30(12):855–857.
- Papaioannou L, Miligkos M, Papanthassiou M. Corneal collagen cross-linking for infectious keratitis: A systematic review and meta-analysis. *Cornea*. 2016;35(1):62–71.

INSTRUCTIONS FOR CE CREDIT

COPE Course ID: 53827-AS
COPE approved for 1.0 credits

Expiration Date: March 2020
CE credit is available electronically via evolvemeded.com

To receive credit, you must complete the Post Test Questions and Activity Evaluation and mail or fax to Evolve Medical Education, PO Box 358, Pine Brook, NJ 07058; Fax: (610) 771-4443. To answer these questions online and receive real-time results, please visit evolvemeded.com and click "Online Courses." If you are experiencing problems with the online test, please email us at support@evolvemeded.com. Certificates are issued electronically, please provide your email address below.

Please type or print clearly, or we will be unable to issue your certificate.

Name _____ OE Tracker Number _____

Phone (required) _____ Email (required) _____

City _____ State _____

UPDATES ON OCULAR SURFACE DISEASE, GLAUCOMA, AND CATARACT COMANAGEMENT CE QUESTIONS

- The main reasons for OSD complaints of foggy or cloudy vision by patients with scleral contact lenses include all BUT:**
 - the lens surface
 - the post lens tear layer
 - the cornea
 - the eyelids
- Plasma treatment on a scleral lens:**
 - is the same thing as lens coating
 - uses oxygen plasma to remove surface particles
 - uses ionized water to remove surface particles
 - increases wetting angles
- The most frequently isolated organism from bacterial keratitis is:**
 - Staphylococcus
 - Streptococcus
 - Pseudomonas
 - Haemophilus influenza
- Even though it has to be compounded for use in ocular formulation, which drug still remains the standard treatment for suspected ocular MRSA infection?**
 - Ciprofloxacin
 - Vancomycin
 - Moxifloxacin
 - Gatifloxacin
- The two main classes of medications used to treat Gram-negative bacterial keratitis are:**
 - Aminoglycosides and macrolides
 - Macrolides and sulfas
 - Aminoglycosides and fluoroquinolones
 - Sulfas and fluoroquinolones
- According to companies that manufacture these products, toric IOLs can provide:**
 - up to 4.00 D of corneal astigmatism (6.00 D of treatment)
 - up to 2.00 D of corneal astigmatism (4.00 D of treatment)
 - up to 4.00 D of corneal astigmatism (2.00 D of treatment)
 - up to 6.00 D of corneal astigmatism (4.00 D of treatment)
- Trifocal lenses use _____ to provide an improvement in _____ vision.**
 - second order add diffractive grating; near
 - first and second order add diffractive grating; intermediate
 - first order add diffractive grating; distance
 - second and third order add diffractive grating; intermediate
- About what percentage of patients discontinue taking ocular medications after 6 months?**
 - 30%
 - 40%
 - 50%
 - 60%
- What are some potential considerations facing optometrists after MIGS procedures? [Choose all that apply.]**
 - IOP spikes
 - intraocular fluctuations
 - occluded stents
 - microhyphema
- What is the typical amount of time postoperative IOP abnormalities take to resolve after a MIGS procedure?**
 - 2 months
 - 3 months
 - 4 months
 - 5 months

ACTIVITY EVALUATION

	Agree	Neutral	Disagree
Did the program meet the following educational objectives?			
Recognize the importance of early diagnosis and treatment of dry eye disease	_____	_____	_____
Assess the role of inflammatory markers/processes in corneal disorders	_____	_____	_____
Formulate strategies to best treat corneal diseases based on the presence of comorbid conditions and/or risk factors	_____	_____	_____
Evaluate disease progression by using novel imaging devices	_____	_____	_____
Identify emerging classes of drugs and their potential advantages over currently used treatment paradigms	_____	_____	_____
Evaluate the safety and efficacy of different treatment modalities for ocular hypertension and primary open-angle glaucoma	_____	_____	_____
Discuss future developments and direction of therapeutics for managing glaucoma	_____	_____	_____

Your responses to the questions below will help us evaluate this CE activity. They will provide us with evidence that improvements were made in patient care as a result of this activity.

Do you feel the program was educationally sound and commercially balanced? Yes No

Comments regarding commercial bias:

Rate your knowledge/skill level prior to participating in this course: 5 = High, 1 = Low _____

Rate your knowledge/skill level after participating in this course: 5 = High, 1 = Low _____

Would you recommend this program to a colleague? Yes No

Do you feel the information presented will improve/change your patient care? Yes No

Please identify how you will improve/change:

Change the management and/or treatment of patients. Please specify:

Create/revise protocols, policies, and/or procedures. Please specify:

Please identify any barriers to change.

Cost

Lack of consensus or professional guidelines

Lack of administrative support

Lack of experience

Lack of time to assess/counsel patients

Lack of opportunity (patients)

Reimbursement/insurance issues

Lack of resources (equipment)

Patient compliance issues

Other. Please specify _____

No barriers