

Supplement to

RT

Retina Today

March 2017

CME Activity

AMD in 2017: A Review of Treatment Guidelines and the Role of Early Appropriate Therapy

Rishi P. Singh, MD, moderator

SriniVas Sadda, MD

Richard F. Spaide, MD

Nadia K. Waheed, MD, MPH

A CME activity jointly provided by Evolve Medical Education LLC, *New Retina MD*, and *Retina Today*.

Supported by an unrestricted educational grant from Regeneron Pharmaceuticals.


evolve
medical education

Jointly provided by Evolve Medical Education LLC, *New Retina MD*, and *Retina Today*.

Supported by an unrestricted educational grant from Regeneron Pharmaceuticals.

Release Date: February 2017

Expiration Date: February 2018

CONTENT SOURCE

This continuing medical education (CME) activity captures content from a roundtable discussion held in September 2016.

TARGET AUDIENCE

This certified CME activity is designed for retina specialists and general ophthalmologists involved in the management of patients with retinal disease.

LEARNING OBJECTIVES

Upon completion of this activity, the participant should be able to:

- Understand the most recent monotherapy and combination therapy clinical study evidence using available anti-VEGF therapies for common retinal diseases, including AMD
- Discuss the ocular and systemic effects of anti-VEGF therapies and how to educate patients on appropriate expectations
- Develop plans to initiate treatment for conditions such as AMD using anti-VEGF agents, as well as better understand when to change therapeutic strategies

ACCREDITATION STATEMENT

This activity has been planned and implemented in accordance with the accreditation requirements and policies of the Accreditation Council for Continuing Medical Education (ACCME) through the joint providership of Evolve Medical Education LLC, *Retina Today* and *New Retina MD*. Evolve Medical Education LLC is accredited by the ACCME to provide continuing medical education for physicians.

AMA CREDIT DESIGNATION STATEMENT

Evolve Medical Education LLC designates this enduring material for a maximum of 1 *AMA PRA Category 1 Credit*.™ Physicians should claim only the credit commensurate with the extent of their participation in the activity.

TO OBTAIN AMA PRA CATEGORY 1 CREDIT(S)™

To obtain *AMA PRA Category 1 Credit*™ for this activity, you must read the activity in its entirety and complete the Post Test/Activity Evaluation Form, which consists of a series of multiple choice questions. To answer these questions online and receive real-time results, please visit evolvemed.com and click "Online Courses." Upon completing the activity and achieving a passing score of over 70% on the self-assessment test, you may print out a CME credit letter awarding 1 *AMA PRA Category 1 Credit*.™ Alternatively, please

complete the Post Test/Activity Evaluation Form and mail or fax to Evolve Medical Education LLC, PO Box 358, Pine Brook, NJ 07058; Fax: (610) 771-4443. The estimated time to complete this activity is 1 hour.

FACULTY



Rishi P. Singh, MD, moderator

Cole Eye Institute, Cleveland Clinic
Cleveland, Ohio




SriniVas Satta, MD

Doheny Eye Institute
Los Angeles, California



Richard F. Spaide, MD

Vitreous Retina Macula Consultants of New York
New York, New York



Nadia K. Waheed, MD, MPH

New England Eye Center
Boston, Massachusetts

DISCLOSURE POLICY STATEMENT

It is the policy of Evolve Medical Education LLC that faculty and other individuals who are in the position to control the content of this activity disclose any real or apparent conflict of interests relating to the topics of this educational activity. Evolve Medical Education LLC has full policies in place that will identify and resolve all conflicts of interest prior to this educational activity.

The following faculty members have the following financial relationships with commercial interests:

Rishi P. Singh, MD, has had a financial agreement or affiliation during the past year with the following commercial interests in the form of *Consultant/Advisory Board/Speaker's Bureau*: Alcon; Allergan Plc; Carl Zeiss Meditec; Genentech; Optos; Regeneron Pharmaceuticals; and Shire Plc. *Grant/Research Support*: Alcon; Apellis Pharmaceuticals; Genentech; and Regeneron Pharmaceuticals.

SriniVas Satta, MD, has had a financial agreement or affiliation during the past year with the following commercial interests in the form of *Consultant/Advisory Board/Speaker's Bureau*: Carl Zeiss Meditec; and Optos. *Grant/Research Support*: Carl Zeiss Meditec; and Optos.

Richard F. Spaide, MD, has had a financial agreement or affiliation during the past year with the following commercial interests in the form of *Consultant/Advisory Board/Speaker's Bureau*: Topcon Corporation.

Nadia K. Waheed, MD, MPH, has had a financial agreement or affiliation during the past year with the following commercial interests in the form of *Consultant/Advisory Board/Speaker's Bureau*: Genentech; Johnson & Johnson; OcuDyne; and Regeneron Pharmaceuticals. *Grant/Research Support*: Carl Zeiss Meditec; Nidek; OcuVue; and Topcon Medical Systems.

EDITORIAL SUPPORT DISCLOSURE

Cheryl Cavanaugh, MS, director of operations, Evolve Medical Education LLC; Emily Feinman, administrator, *New Retina MD* and *Retina Today*; Michelle Dalton, medical writer; have no real or apparent conflicts of interest to report.

David Friess, OD, FAAO, peer reviewer, has had a financial agreement or affiliation during the past year with the following commercial interests in the form of *Employee/Stock Shareholder*: STAAR Surgical Company.

OFF-LABEL STATEMENT

This educational activity may contain discussion of published and/or investigational uses of agents that are not indicated by the FDA. The opinions expressed in the educational activity are those of the faculty. Please refer to the official prescribing information for each product for discussion of approved indications, contraindications, and warnings.

DISCLAIMER

The views and opinions expressed in this educational activity are those of the faculty and do not necessarily represent the views of Evolve Medical Education LLC, *New Retina MD*, *Retina Today*, or Regeneron Pharmaceuticals.

Go to evolvemeded.com/online-courses/ to view the online version of this supplement.



AMD in 2017: A Review of Treatment Guidelines and the Role of Early Appropriate Therapy

Despite the development of treatment options for common retinal diseases and the published results of many pivotal studies for these diseases, clinical experience and real-world dosing methods continue to vary and treatment remains a challenge. This roundtable addresses some of these challenges and examines outcomes of the clinical trials versus what retinal specialists encounter in clinical practice, the implications of stopping treatment, the importance of distinguishing between macular and geographic atrophy, and the contribution of monitoring technologies and what they offer. The panel also discussed the challenges inherent in reading images and determining treatment in their review of several patient cases.

—Rishi P. Singh, MD, moderator

OUTCOMES IN STUDIES VERSUS OUTCOMES IN CLINICAL PRACTICE

Rishi P. Singh, MD: Several great studies came out recently, including the CATT 5-year data,¹ SEVEN-UP,² the extension trials of VIEW 1 and VIEW 2,³⁻⁵ and the RANGE study.⁶ Today, I would like us to examine several issues: (1) general long-term age-related macular degeneration (AMD) treatment—what we expected and what we actually saw; (2) the burden of geographic atrophy (GA) on our AMD patients, its pathogenesis and the theory behind it; and (3) technological improvements for management with a focus on optical coherence tomography (OCT) angiography and how we use it in practice.

We have had anti-VEGF therapy for many years now. Do you find the same sort of results in your clinical practice that we read about in recent studies?

Richard F. Spaide, MD: For one, several of the studies do not reflect how we practice. The SEVEN-UP study² provided 1.6 injections per year and the PACORES study⁷ provided two injections annually. One would not expect these patients to do well with so few injections. On the other hand, the Peden study⁸ provided continuous dosing over a long period of time, resulting in considerably better outcomes. Patients in the Gillies⁹ and Rasmussen¹⁰ studies who were treated five or six times per year also fared better.

SriniVas Sadda, MD: I agree with you, but bear in mind that these studies had mixed populations. There are many who remained undertreated, but this is a complex issue. In some cases, the patient just did not return for treatment.

Dr. Singh: In short, the fewer the injections that were provided, the worse the outcomes.

Dr. Spaide: I reviewed some of the patient series. Even though

some patients came in several times, they were not given injections. To me, that means these were prn protocols.

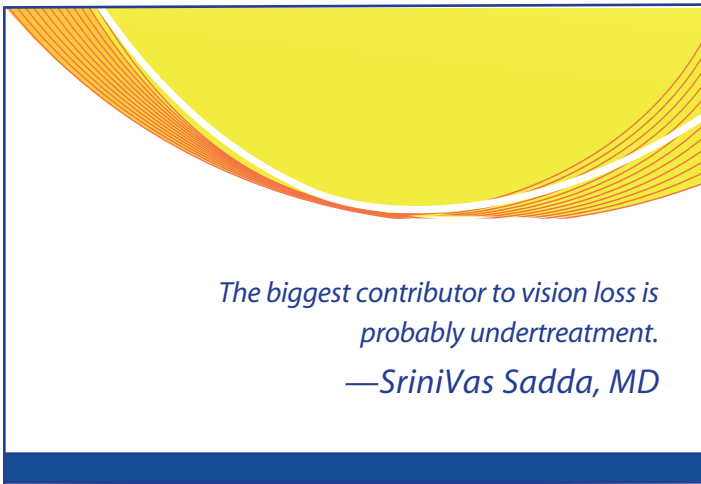
Dr. Sadda: There is no question that this occurs; however, if you look back at the SEVEN-UP data,² we can see that we sometimes have patients with significant areas of atrophy.

Dr. Spaide: Just because patients end up with atrophy that does not mean they should not have been treated with anti-VEGF sooner or more often. Although treatment with an anti-VEGF may be associated with development or progression of atrophy that does not mean undertreatment is associated with less atrophy. If a patient has large areas of exudation, it is possible for them to have scarring, fibrosis, or atrophy as a consequence. We know from studies with more frequent treatment (Gillies or Rasmussen) that there is less vision loss over time.

Dr. Sadda: True, but I am suggesting that even if these patients had been treated, they would still have ended up (potentially) with long-term vision loss.

Nadia K. Waheed, MD, MPH: I agree that undertreatment is probably a huge threat to vision and the biggest cause of vision loss in the short-intermediate term, hands down. I do think, however, that in the post-anti-VEGF era, atrophy will be an enduring challenge and many patients may still lose vision in the long term despite adequate treatment of wet AMD.

Dr. Singh: The RANGE and VIEW 1 extension studies were capped prn studies. Consequently, they provided a higher frequency of injections. It could be that undertreatment late in the disease state was the cause of the poorer outcomes and increased atrophy. Selection bias might also have played a role. We have patients we continue to treat over a long term because they are just doing



poorly or just have bad vision. Nonetheless, we keep treating them in the hopes they will do better.

Dr. Sadda: I do not think selection bias is at play here. I think the results are poorer because, as Dr. Spaide suggested, patients are undertreated. The biggest contributor to vision loss is probably undertreatment. That said, do you think the natural history of this condition, if left unchecked, is atrophy resulting in AMD?

Dr. Spaide: Absolutely. If you oxidatively stress retinal pigment epithelial cells, they make VEGF. With further oxidation and stress, the cells die. We think oxidative damage is one of the cornerstones of AMD pathogenesis.

Dr. Sadda: With VEGF, choroidal neovascularization is the response. The body probably has a reason for doing this.

Dr. Singh: What is your strategy for avoiding this situation? Are you employing a capped prn in your practice, where you mandate injections every 3 months?

Dr. Sadda: Treat and extend? No, I do not do that. Instead, I start by treating prn, but I do frequent follow-ups (monthly). The only way I can ensure good outcomes is to see my patients frequently. For patients who cannot come in frequently, I use a treat-and-extend approach. Also, if I observe a very robust recurrence, I may consider switching to a treat-and-extend approach because I do not like seeing large anatomic oscillations. Otherwise, I will treat prn, but I do not cap them. I do not treat any patient mandatorily. I think this is a safe way of approaching the problem.

Dr. Spaide: We are talking about a minority of patients. Most require treatment every 4 or 6 weeks, even on a treat-and-extend basis. If a patient has one good eye, I am more willing to extend the treatment even further out and provide treatment every 3 months. I tell my patients that we just do not have all the answers and try to include them in the decision-making process.

Dr. Waheed: I am primarily a prn treater and I do see my patients every 4 to 6 weeks and image them with OCT at every visit to see

how the anatomy is changing. I maintain a very low threshold for treating. I will occasionally treat and extend if there is a patient reason to do so. I think Dr. Spaide touched on a very important point here. With prn treatment, it is critical to enroll our patients as partners in treatment because it is very easy for them to get exhausted with the frequent visit schedule as well as the unpredictability of whether they are getting injections or not at the visit.

Dr. Singh: What do you tell physicians who read all the data and figures and the results look bad. How would you counsel them to reduce their chances of having patients lose vision over time? Would you recommend frequent monitoring?

Dr. Waheed: I would recommend frequent monitoring and a very low threshold for treatment.

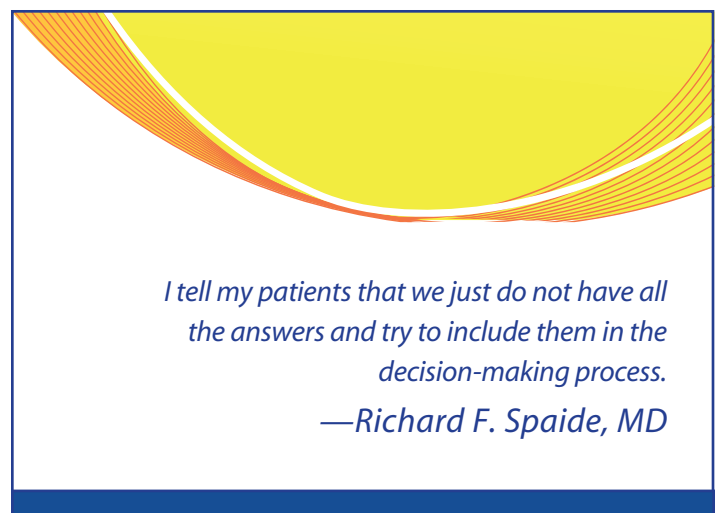
Dr. Sadda: I would recommend frequent monitoring and treating patients when there is activity.

Dr. Singh: There are home vision-monitoring systems: the PAXOS device or ForeseeHome, which is the only FDA-approved device for monitoring of nonexudative AMD. Is monthly monitoring in the office sufficient?

Dr. Sadda: Some people are developing home OCT devices to automatically detect fluid activity. I do see more of this type of monitoring occurring, and there may be opportunities for more people to be put on a modified prn strategy. This might be a good way of detecting recurrence at the earliest possible time. Can you imagine putting patients on a sustained-release device that would release anti-VEGF on demand, perhaps even telemetrically?

Dr. Waheed: That would be brilliant and the ultimate solution, similar to what is happening with insulin pumps. It is a long way from being in clinics as yet, though.

Dr. Spaide: Of course, cost would be a factor. It must be reasonable.



WHEN TO STOP AND WHEN TO CONTINUE TREATMENT

Dr. Singh: Another problem facing us is that despite injecting patients for several years, many still lose their vision. What about the patient whose vision is 20/200 or 20/100? How or when do you decide to stop treatment?

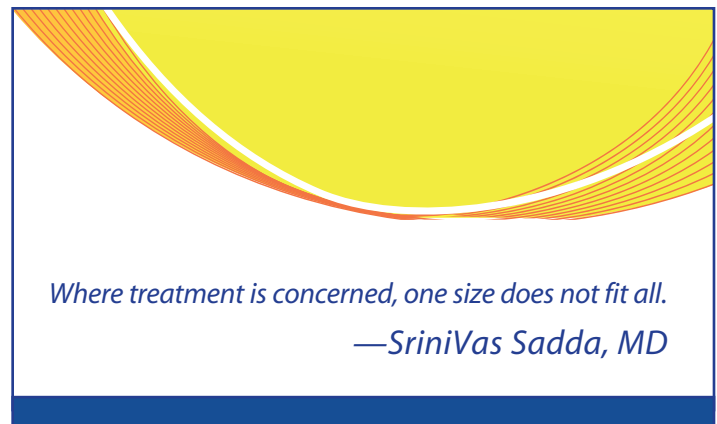
Dr. Sadda: This is a difficult question, because there is no cut-off. Many things must be factored in, including individual patient response, the patient's overall functionality, and how the other eye responds. Patient values are a big part of the picture. Patients who are in the low-counting fingers range do not tend to benefit substantially from treatment. That said, it is possible to have a patient who has what looks like a large fibrotic lesion, despite therapy, or a large patch of atrophy and who develops a new eccentric hemorrhage and evidence of activity. Will such a patient benefit from treatment? Part of my decision with such a patient might depend on where the new activity occurred. I might choose to continue treating a patient who has developed a new area of activity close to an eccentric fixation point, even though the vision is poor. Where treatment is concerned, one size does not fit all.

Dr. Spaide: Yes—if a patient has a big area of atrophy surrounding a relatively smaller scar and no chance for an extension of neovascularization through that moat of atrophy, but the center is fibrotic and dry, you may be able to stop treatment and closely follow the patient. I almost never stop treatment. Rasmussen and colleagues did stop treatment in one study because of disease inactivity.¹⁰ Further treatment was thought futile. Unfortunately, the patients' vision declined. Who is to say what should be done? There is no gold standard here. If the patient has a good fellow eye, treatment might seem unnecessary from the patient's point of view. Still, your goal must be to preserve whatever vision you can for the patient. We cannot predict the future and there is a possibility the good eye could decompensate.

Dr. Waheed: Keep in mind that although visual acuity is the only real functional measure we look at, it is only part of the patient's experience. Activity that may not affect visual acuity, such as around areas of scarring or into an area of eccentric fixation can be a real problem for the patient. I think you have to individualize stopping treatment and have a real discussion with the patient regarding the implications of stopping. I am much more likely to consider stopping if the patient has a good fellow eye, but even in that situation, AMD is a bilateral disease and a good eye today may not be good down the road.

Dr. Singh: What are your recommendations at the other end of the spectrum, where vision is good but activity is present? For example, how would you treat a patient who is 20/20 and asymptomatic with a new lesion and evidence of exudation?

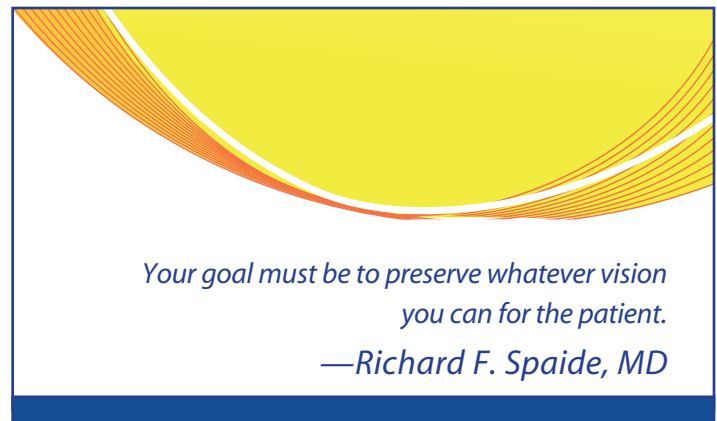
Dr. Sadda: I always think twice before treating an asymptomatic patient. Evidence of hemorrhage would modulate my decision and sway me toward treating a patient or suggesting treatment. The problem arises in demonstrating a benefit from treatment. This is difficult in an asymptomatic patient. So I usually identify something and



direct the patients to identify a distortion or something, particularly if there is a lot of fluid. I would be less inclined to treat an eccentric lesion with little fluid, unless it was threatening the center fovea.

Dr. Waheed: In asymptomatic patients with macular lesions that show intraretinal or subretinal fluid on OCT that could threaten the fovea, I usually favor treating. Sometimes I will do very close follow-up to demonstrate progression. If there is progression, I will treat. The risk of treatment is low and there is enough evidence to show that early treatment while the lesion is presumably still small can be valuable.

Dr. Spaide: Hanutsaha et al in our group looked at 432 patients with indocyanine green angiography (ICG) to image choroidal circulation.¹¹ A fair number of patients had plaque, which were presumed to be choroidal neovascularization (CNV), despite little direct evidence. Nonetheless, after more than 20 months of follow-up, these patients were more likely to show signs of exudative disease than in patients with no sign of plaque. Back then, diagnosis was not OCT-driven. Today, we have much more sensitive means of detecting disease, and we can observe



patients more closely for signs of disease activity. If a patient has fluid of any type, I usually treat it. Fluid is an early sign of disease activity because the patients probably did not have fluid prior to the neovascularization. If you catch a patient early and with a small lesion, you can treat them once or twice to dry the eye.

Dr. Sadda: But we should be clear that there is no evidence to support treating these patients. In the studies for which we enroll patients,

there is always evidence of activity. So, I will sometimes wait. For example, a patient I saw recently had a small area of CNV demarcated. She oscillates, and every few months she burps up a little fluid, which then goes away. Over time, I would have expected the intervals between the fluid increase to shorten, but they have not. Sometimes nothing happens in these patients. Although CNV can be bad, it is not always bad.

ATROPHY—MACULAR OR GEOGRAPHIC?

Dr. Singh: What are your thoughts about atrophy in these patients?

Dr. Waheed: I generally use macular atrophy in the context of neovascular disease and GA in the context of non-neovascular AMD. They may well be part of the same underlying pathogenic process with some eyes detouring to neovascularization along the way.

Dr. Sadda: The term GA might be reserved for the setting of non-neovascular disease.

Dr. Spaide: GA has sharply defined borders that are slightly depressed and where you can detect underlying choroidal blood vessels in color photographs. In the context of CNV, does the area have to be sharply defined?

Dr. Sadda: Do you even have to be able to see the choroidal blood vessels?

Dr. Spaide: Perhaps there is no basis for knowing that the area must be sharply defined. Back in 2012, we published a study in which we looked at consecutive patients who came into our office.¹² We conducted autofluorescence on all patients to determine their baseline acuity and compared it after VEGF treatment 3 years later. The biggest predictor of change in visual acuity was the change in size of the area of loss on autofluorescence. Consequently, we do not call it GA; since the diagnosis was not based on color photography.

Dr. Singh: In the HARBOR and CATT studies,^{13,14} many patients developed macular atrophy over time. What would you say are the key takeaways from those studies with regard to the progression of disease?

Dr. Sadda: First and foremost, you do not withhold treatment for fear of atrophy. In spite of atrophy, patients' vision can improve. Second, we know that atrophy is the endstage of AMD, meaning that this is where the patients are headed. Atrophy is a normal part of aging. As you age, parts of your body will atrophy, just like your macula. If you have AMD, however, you will experience macular atrophy sooner than a healthy person. Along the path to atrophy, some people develop CNV, which may be the body's response to ward off atrophy. This is my belief, but I do not have data yet to support it.

Dr. Spaide: Similarly, choroidal thickness decreases with age.

Dr. Sadda: Choroidal atrophy is clearly a risk factor for CNV, and we do have data to support this. Let us examine instead pathologic myopia. Pathologic myopes who develop CNV have

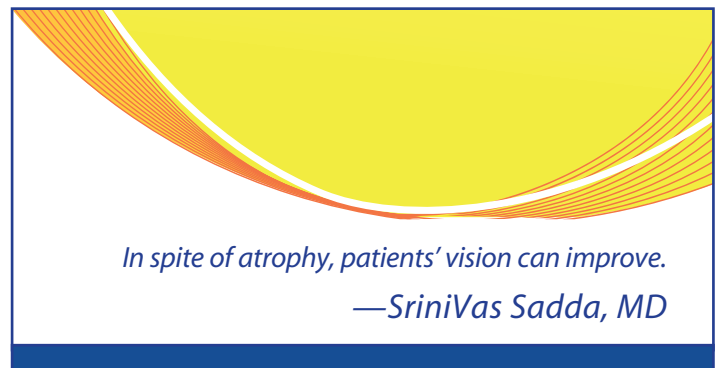
a thinner choroid than pathologic myopes without CNV do.¹⁵ It seems intuitive that having a thinner choroid poses a risk factor for eventual problems, including developing CNV.

Dr. Waheed: I keep going back to the fact that undertreatment is still the biggest threat to a patient's vision. However, the data on atrophy does emphasize that despite successful treatment with anti-VEGFs, we are not halting the disease and patients may still lose vision in the long term.¹⁶ We have looked at the choriocapillaris underlying the areas of atrophy in patients with GA and macular atrophy and seen that there is a loss of flow in the choriocapillaris underlying these areas of atrophy. What is interesting is that there is also a slowing of the blood flow in the areas surrounding atrophy, which makes us question whether hypoxia may be driving some of the AMD changes that we see. Moreover, patients with nascent GA as well as certain patients with drusen were also noted to have flow alterations underlying the areas of nascent GA and the areas of drusen.

Dr. Spaide: By mathematically analyzing the choriocapillaris, it is possible to detect changes in flow features by age, vision, the presence of hypertension, pseudodrusen, and also if the patient has late AMD in the fellow eye. You can tell the difference between patients with late AMD in their fellow eye and those who do not have this disease.

Dr. Singh: You are associating disease progression with choroidal thickness. Recent findings from the HARBOR study show that the presence of subretinal fluid is a positive prognostic indicator.¹⁷

Dr. Sadda: This is a really important point. I think some people have taken that to mean that fluid is good and that treatment is not necessary. If you have fluid, you must treat. Fluid is the canary in the coal mine calling your attention to an active lesion. In the HARBOR and CATT studies,^{13,18} we observed that patients in the prn arms had less atrophy; however, it turns out that patients in the prn arms who had the least atrophy received the most injections. This seems incongruous on first glance. I think patients who were being treated more had active lesions with evidence of CNV. Looking at it this way, CNV has a potentially positive effect: you have a lesion that is being controlled by continuous treatment, but because the lesion is still there perhaps it is protecting against atrophy.



Dr. Spaide: CNV is a life cycle that is induced by living tissue. Cells that participate in CNV can become atrophic. A hypovascular scar develops in the late stage of disease, but it is a dead scar and incapable of producing fluid. Only living tissue can produce fluid.

Dr. Singh: How real do you think vision loss is from macular atrophy in this setting? If you look at the CATT findings, the majority of macular atrophy was nonfoveal.^{9,14} Is this really an issue or is it just part of the natural history of the disease?

Dr. Sadda: As I mentioned, patients who develop atrophy can still gain vision. This is consistent across all studies. Primarily the atrophy was nonfoveal, at least during the time frame of the study. Many patients, in fact, have foveal resilience, where the fovea stays intact to the end. Some patients, however, may have foveal involvement with atrophy. It takes a long time to see the consequences of this in terms of visual acuity.

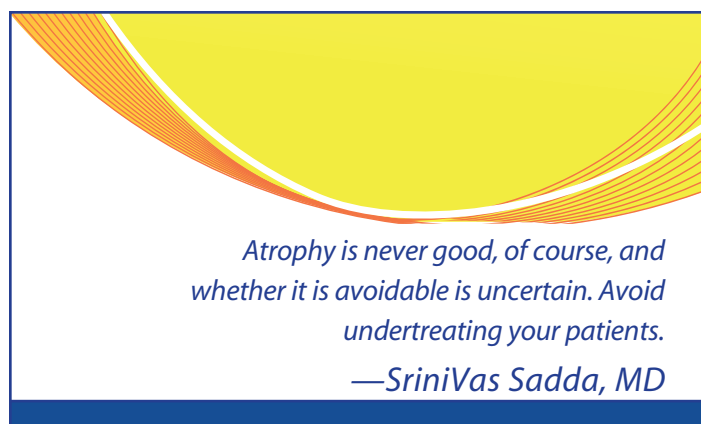
Patients who have undergone long-term continuous treatment have fairly good visual outcomes. This is not to say they are not developing any atrophy, since visual acuity can still be good provided the atrophy is not in the center. Atrophy is never good, of course, and whether it is avoidable is uncertain. The one message I would hope to convey is to avoid undertreating your patients. The message I give patients is that treatment will probably not “cure” their condition, but it can help stabilize and perhaps prevent further loss of vision. The patients with the best outcomes are those with a stabilized type 1 membrane with an intact retinal pigmentation over it with relatively small recurrences of fluid, if any. Those patients do not tend to develop atrophy and do well over the long term.

Dr. Spaide: Several years ago, we did a study using a multimodal imaging approach in patients with CNV.^{19,20} We used the Early Treatment Diabetic Retinopathy Study²¹ charts to measure visual acuity, reading speed, contrast sensitivity, and microperimetry. The area of lost autofluorescence is the biggest predictor of reading speed and contrast sensitivity. So patients with larger areas of atrophy have a harder time reading. Even though they can read letters on an eye chart, they might be unable to read 100 words per minute in order to be considered fluent readers.

Dr. Waheed: Which comes back to the issue that visual acuity is not the best or most sensitive gauge of visual function in real-life situations.

Dr. Sadda: In neovascular AMD patients, decreased autofluorescence is a challenge, since you cannot distinguish between areas of fibrosis or atrophy. If you treat patients on a prn dosing schedule, I recommend looking at your individual OCT B-scans. I always err on the side of caution and treat. When in doubt, treat. In a patient with a very thin choroid or evidence of atrophy, I might ask them to come back soon, perhaps in 3 weeks, for a repeat examination in case I decide not to treat.

Dr. Spaide: I use treat-and-extend regimens, but I provide prn treatment often. Generally at 2 months, I extend the follow-up without giving a treatment and then call the patient back again for



another examination. It is difficult to get a handle on how long it is going to take. Instead of injecting patients who have a lot of atrophy but no activity, I use a prn treatment regimen. After all, an injection could worsen the atrophy.

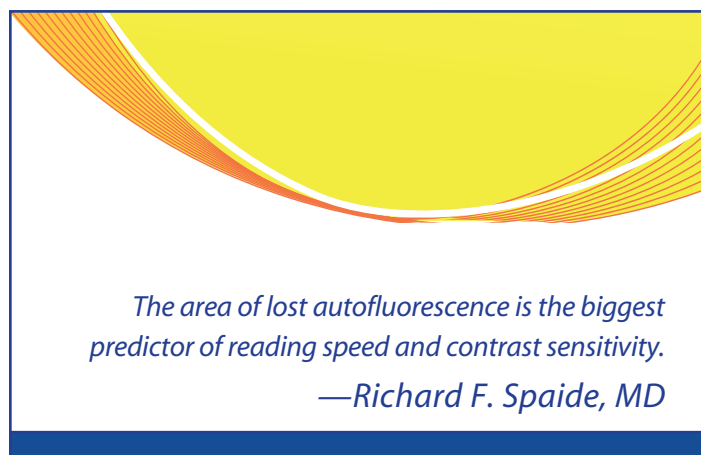
MONITORING TECHNOLOGIES

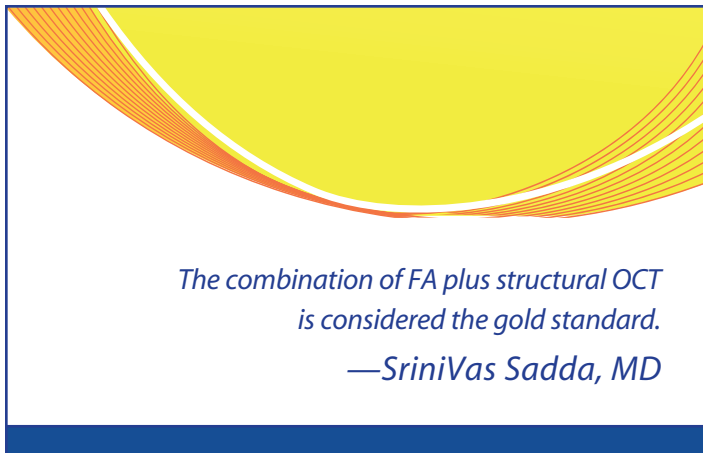
Dr. Singh: What about the patients who have GA? What technologies do you use to monitor them? Most of us are probably doing serial OCTs on patients with neovascular AMD. But are we doing any other kind of analysis on these patients? Are you looking for atrophy on the OCT? Are you adding fundus autofluorescence or other modalities?

Dr. Spaide: We do autofluorescence or fundus angiography in our office. We do green light autofluorescence imaging once every 6 months.

Dr. Waheed: I tend to minimize tests that will not change management, so I generally stick to doing OCTs around every 6 months in patients with GA. The purpose of that is just to monitor GA size and get an idea of its rate of growth. I do not do much autofluorescence at all in these patients, and once the GA involves the fovea, I may not even do OCT unless I see a reason to.

Dr. Sadda: We do not tend to do much fundus autofluorescence, mainly because patients complain about it; however, I should do it more often. With the green light, it is not so bad. Patients tolerate it





less when we use the blue light.

I do not necessarily look at the advanced retinal pigment epithelium (RPE) analysis on OCT or look for atrophy every time, but every few months I review the measurements. I am obviously getting an OCT every time the patient comes in. Every several months, I look to see if the atrophy is increasing. Just as there is a variation among dry AMD-GA patients with respect to the atrophy progression curve, there is also a variation among neovascular AMD patients. We have tracked atrophy with monthly OCTs, and it does reveal an enlargement over time, albeit slower than what we see with a dry AMD-GA patient.

Dr. Singh: What does OCT offer your patients?

Dr. Spaide: OCT is a marvelous way to research the retina and learn many things about it. Identifying a vascular abnormality was severely limited by fluorescein, and ICG provides low contrast and limited resolution. In a practical sense, I do not think you gain a lot by going to OCT angiography now for many diseases in the way we treat them. There are few studies that offer us a perspective of treatment outcome effects in relationship to whatever we find by OCT angiography. This new technology might be useful in patients with a thick choroid, but I do not think it is going to offer a driving point for many years. What it will help us do is develop new ideas and models of disease, which will drive the next generation of treatments.

Dr. Sadda: I agree. For one, the technology is still maturing, and the algorithms are still evolving. There are too many artifacts with OCT angiography, the most challenging of which is projection artifact.²² It can affect how we can interpret the data in many ways. We are sorely lacking prospective studies that can pinpoint features of OCT angiography that should influence our treatment decisions. Having said that, many studies have been published on the sensitivity and specificity of OCT angiography in detecting CNV.²³⁻²⁵ People have now started to question whether fluorescein angiography (FA) is the gold standard, which it likely is not. It is the combination of FA plus structural OCT that is currently considered the gold standard. Regardless, in the absence of more data, the best way to use OCT angiography is not clear. I am restricting my comments to AMD, not to identifying nonperfusion and retinal vasculature, where I firmly believe OCT angiography has a role to play. It is also useful when the

angiogram is somewhat equivocal, as in patients with pachychoroid neovascularopathy. I find OCT angiography particularly helpful when the FA is murky; however, you do have to be certain there is nothing in the choroid or the retinal vasculature.

Dr. Waheed: I find OCT angiography incredibly useful in the diagnosis of CNV. If I have an OCT suggestive of CNV, I will get OCT angiography and look specifically at the area of interest to identify the CNV. It acts as an intermediate step between OCT and FA, and if it is positive, it often obviates the need for FA. I also use it to monitor treatment response in patients with CNV. But I think it needs to be incorporated in clinical trials before we can start using it in a meaningful way to be a major driver of treatment algorithms.

Dr. Spaide: When looking at type 1 CNV, especially in the early stages, it is difficult to see the full extent of the vessels initially with OCT angiography.

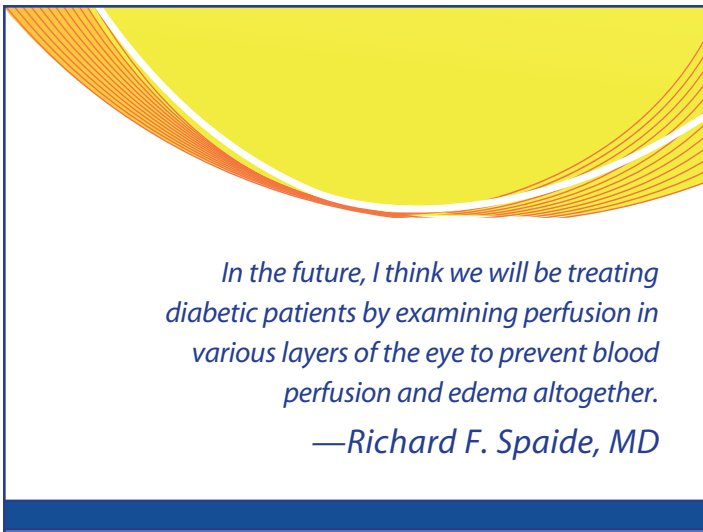
I have been working with a reading center to see if they will use OCT angiography as an initial tool. You can examine late-phase fluorescein and see stippled hyper-fluorescence and get an idea that it is CNV and its size in 30 seconds, or you can spend many minutes looking at OCT angiography B-scans with flow overlays.

Dr. Singh: Many people are buying this technology and using it, but they are also struggling with trying to figure out how to use it in clinical practice. What do you recommend? How do you view your OCT angiography images now? Do you go to the machine? Do you print things out? Do you look through a viewer?

Dr. Spaide: In our office, you can look at any image of any patient on any computer. We do not go to any instrument to see the images.

Dr. Sadda: Unfortunately, our machines do currently not provide all of the manipulations and information you need to always interpret OCT angiography accurately. Dr. Spaide led an initiative at the Macular Society to assemble a group of advanced users to classify these lesions and how we look at them. One of the recommendations from this effort was to suggest a way of looking at the data where you have a four-panel overlay—structural en-face, flow, OCT angiography en-face image, and B-scan flow. It would be nice to have greater confidence that we are not looking at segmentation or a projection artifact, which could lead to greater accuracy in the image's interpretation. The challenge remains that the segmentation boundaries must be adjusted manually. This does require time and effort, and is difficult to do in the middle of a busy clinic. So far, I only take the time in the middle of clinic to look at a handful of cases. Most of the time, I am looking at the data after clinic is over.

Dr. Waheed: Let me be the dissenting voice here and say that you cannot really exploit the full potential of OCT angiography without looking at the complete data set and being able to manipulate it. The segmentation algorithms are not robust enough as yet. When looking for CNV, I generally like to focus on the areas of interest identified on a B scan, such as a pigment epithelial detachment. I



In the future, I think we will be treating diabetic patients by examining perfusion in various layers of the eye to prevent blood perfusion and edema altogether.

—Richard F. Spaide, MD

then like to evaluate both a combined outer retinal and choriocapillaris slab as well as a thin choriocapillaris slab to evaluate for the presence of CNV. I also then look at the flow overlaid on a B-scan because it helps me identify whether what I am seeing is an artifact or whether it is real flow. Any flow between RPE and Bruch's or above Bruch's in the outer retina signifies CNV.

Dr. Spaide: When we treat patients, we are treating them based on standards set in the 1980s. We are still talking about different numbers of steps for the diabetic retinopathy severity score. When we look for edema, we look for simple things, such as thickening. In the future, I think we will be treating diabetic patients by examining perfusion in various layers of the eye to prevent blood perfusion and edema altogether. We will probably have some way to predict outcomes based on OCT angiography, because we will certainly not be able to do it with fluorescein, ICG, or even structural OCT. But with OCT angiography, we might reach a point where we can predict that a certain percentage of patients will have macular edema in 2 years. Then we can begin treatment to prevent the progression of disease.

Dr. Sadda: For us to arrive at that point and leave the 1980s, we need data. I think it is important to have more people using the technology, and obtaining it. It sort of comes free when you are obtaining your other scans, and the process takes little time. We have a great opportunity here to collect data and use those data in large studies to test the validity of our predictions. It is important that people use the technology so that we can amass the necessary information, because this is where we are headed.

Dr. Spaide: It took more 20 years and a lot of brainpower from when FA was invented to reach the point where we could tell classic versus occult CNV. OCT angiography has only been in place for 2 years and it is already a nearly commonplace technology.

Dr. Singh: Can OCT angiography replace FA?

Dr. Sadda: If I had a patient with retinal vascular disease (RVD) in whom I am looking for nonperfusion of the macula, I think OCT

angiography would be highly effective. We get much more detail than we would with standard fluorescein. I think it is headed that way for some optic nerve disorders that affect the radial peripapillary capillary network. I think there are many applications where we might not use FA. Of course, OCT angiography does not completely replace FA in treating RVD, since it does not yet show us leakage.

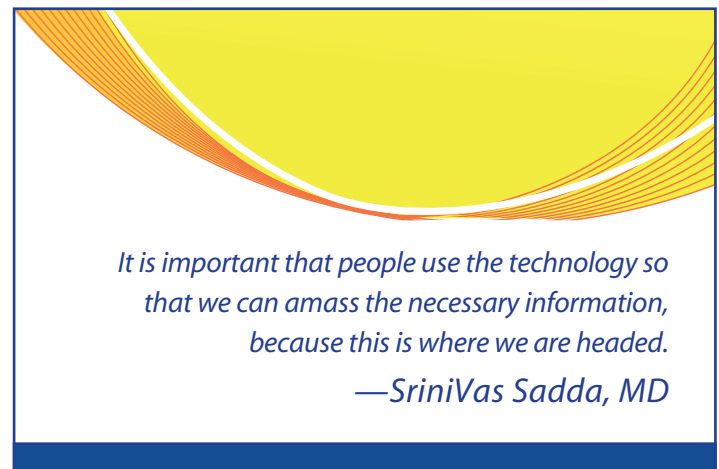
Dr. Spaide: If you had structural OCT, would you need FA?

Dr. Sadda: I do not know if you need structural OCT to assess nonperfusion. You can do that very well now with OCT angiography. It is also quite useful for RVD because you are not dealing with issues of projection and light, especially for the superficial layers.

Dr. Waheed: I think in many applications, OCT angiography provides you with information that is as good as or better than what you are getting with FA. And I think the combination of OCT angiography with structural OCT gives you all the information you need to make treatment decisions in most people with RVD. However, in some patients, such as those with bad motion artifact, FA may still be useful. So I think that OCT angiography will replace FA in many—but not all—situations.

Dr. Singh: Which OCT angiography device has features you prefer? Do you favor one device over the other?

Dr. Spaide: Each machine has its own attributes. The Zeiss Cirrus HD-OCT seems to be the easiest to use. It offers fairly good imaging. We do not have the higher end machine, just the spectral domain machine. Retina vascular-wise, it is easy on the patients and it offers very good tracking. However, I think the image quality is less than optimal, particularly for the choriocapillaris. There is an unusual



It is important that people use the technology so that we can amass the necessary information, because this is where we are headed.

—Srinivas Sadda, MD

gray scale with the Zeiss OCT. I think the Topcon 3D OCT-1 is very good, but the user interface is not as nice. You must switch from one program to another to look at it. One system is hardware-based, the other is web-based. The Optovue iVue Spectral-Domain OCT produces a good image and has some interesting software extensions. The tracking is not particularly good, but it has software correction to fix some of the resultant problems.

Dr. Waheed: I think all the machines have strengths and weaknesses and all are evolving rapidly. I like both the Zeiss and the Topcon machines. We also have the Optovue Avanti and it generates excellent patient images, has great motion correction using a combination of a tracking feature and software-based correction, and allows for quantification of the retinal vessels, which is really useful in RVD such as diabetes. We also have the prototype Zeiss swept source machine, the Plex Elite, which has an easy user interface, excellent eye tracking and motion correction, and can get widefield high-resolution scans that are really useful for RVD. And the Topcon 3D OCT-1, in addition to what Dr. Spaide said, provides multimodal imaging with the ability to get color fundus photos and fundus autofluorescence in the same machine.

Dr. Sadda: The machines are in the process of evolving with regard to ease, speed, and ergonomics of the visual interface. All of these things can, of course, affect how easily you are able to acquire data.

Dr. Spaide: If one company creates software, the next company is going to copy the good points of that software very quickly. The hardware platforms do not change as rapidly.

Dr. Sadda: The value of the spectral domain versus the swept source is an interesting subject. We do not have very good studies comparing the value of one over the other in imaging the retinal vasculature. I do not think there is much difference in this regard between the two types.

There is, however, an advantage of the swept source in having less attenuation of signal to depth. If you have a patient with significant edema and you are trying to view the deep plexus displaced at the bottom of a huge cyst, you can potentially resolve it more easily with swept source. The speed gap between the commercial swept source devices and the best spectral domain has really narrowed. This is a big factor.

With respect to the depth of penetration, I think there is some value in looking at some of the deeper parts of the choroid with swept source. Most spectral domain swept source devices do a good job of imaging the choriocapillaris, but again, if you have a thickened retina, the swept source is better in that setting. Also we do not see medium-sized vessels, such as Sattler's layer vessels, that well with SD-OCT angiography. With good quality swept source acquisitions, we can actually make out the signal in Sattler's. There is something to be said for the depth of penetration.

Confocal imaging has great advantages since it analyzes only one plane of information. One of the reasons that autofluorescent imaging has taken off for assessing atrophy is because of the great contrast it provides. Sometimes it is difficult to detect the edge of the atrophic lesion, but with confocal imaging we can define the borders of atrophy in a high percentage of cases. It has certainly changed my perspective on color imaging and its usefulness in studying disease.

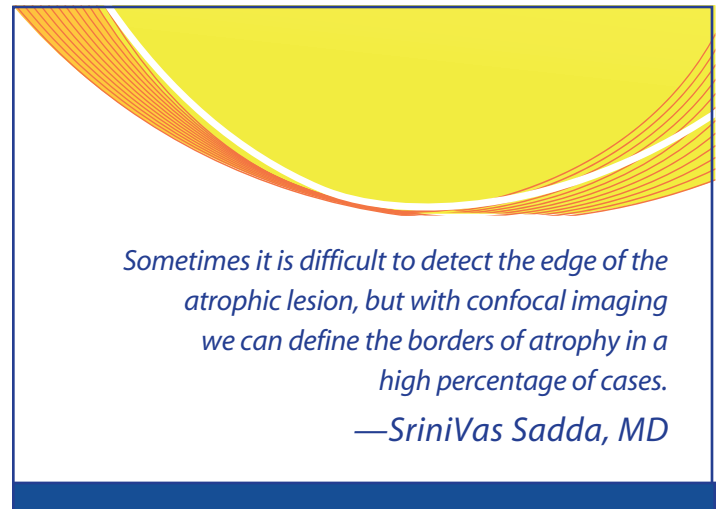
The CenterVue Eidon system, which uses confocal white light, also has autofluorescence capability. In terms of images, the quality is good and it uses a green light. Optos OCT offers a confocal system, as does the Nidek F-10 system. The Nidek SC1600 system chart and Optos and Heidelberg systems are multimodal.

A promising technology, however, is optophysiology. This allows us to do functional assays using the OCT as we look for reflective changes that are not motion-related. The challenge with this technology is that it requires very precise high-frequency tracking.

Another area that I am excited about is hyperspectral imaging. We primarily use 840-nm and 1040-nm light bands for OCT, relatively limited amounts of the available bands, but there are many other bands we can do OCT imaging on. These other bands could potentially be sensitive to specific molecules that may be relevant to various diseases. One molecule for which hyperspectral imaging is already in use is oxygen. Oximetry in a depth-resolved fashion using OCT is an exciting potential future application.

Dr. Spaide: There are a variety of densities for scanning laser ophthalmoscope that will allow you to see cones outside the fovea. It is a fast examination, unlike what we get with adaptive optics (AO). We bought an AO instrument that is disappointing in this respect; however, there are technical benefits to adding AO to OCT, including providing ultrahigh 3D cellular resolution at high speeds. The software will continue to improve. OCT angiography will also improve. Today, we have to flatten specimens to look at blood vessels that exist in a volume. The volume increases in diseased tissue, as in diabetic macular edema. So we do not have a good idea what profusion is like because we cannot segment the tissue correctly or estimate blood vessel densities per unit volume. We know that oxygen diffusion is clearly affected by distance. We need to have technology that will allow us to examine the volume of tissue we are attempting to analyze.

Still, we have come a long way. With hyperspectral imaging, we can now image some of the things Eldred and Katz attempted to image in their less sophisticated, but prescient way in the late 1980s.²⁶



CASE STUDIES

Dry AMD and Cataract

Dr. Singh: Here is the case of a 58-year-old man who was observed for cataracts and intermediate dry AMD with drusen (Figure 1).

Dr. Spaide: To make a diagnosis of AMD, you must see drusen—many intermediate drusen or one large druse—but they are missing here. This patient is in the pachychoroid spectrum of the disease.

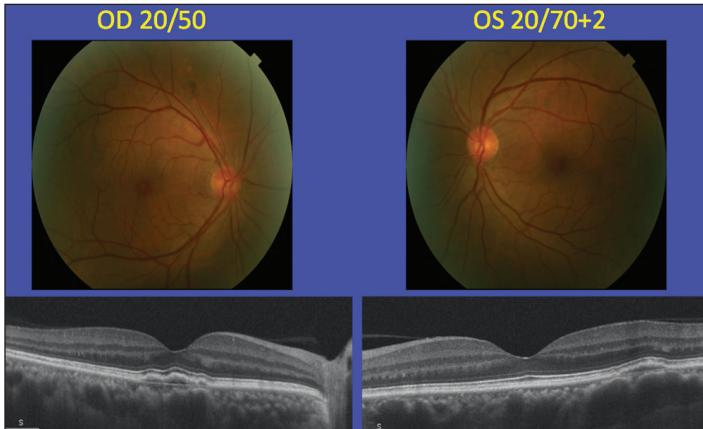


Figure 1. A 58-year-old man who was observed for cataracts and intermediate dry AMD with drusen.

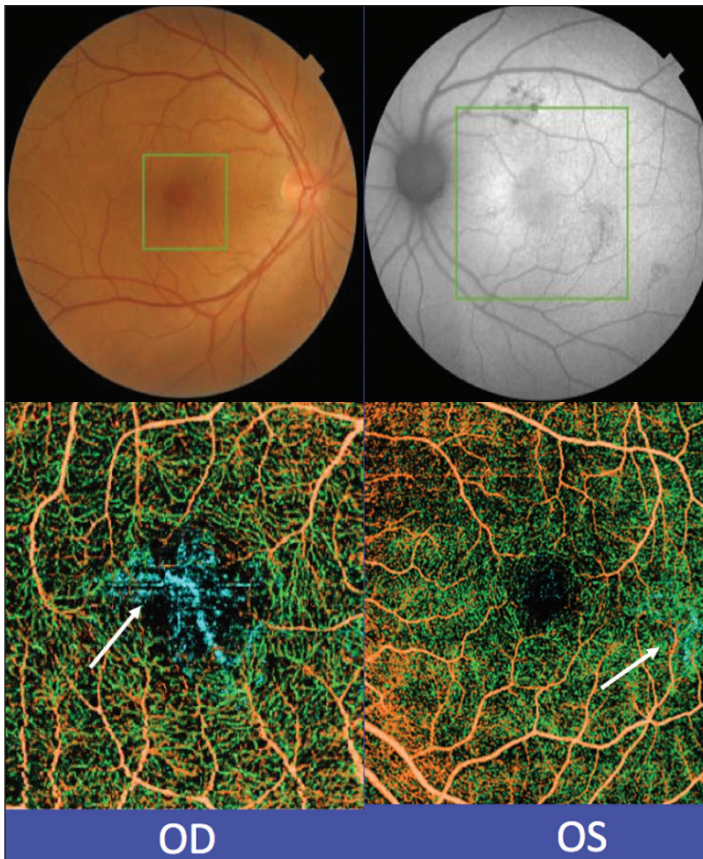


Figure 2. OCT angiography of a 58-year-old man.

There appears to be a heterogeneous reflection coming from the sub-RPE space.

Dr. Singh: This appears to be early pachychoroid neovascularopathy.

Dr. Spaide: Figure 2 shows the vessels we are talking about. What makes it difficult to see the depth in this OCT angiography are the poorly chosen colors.

A Case of Known CNV

Dr. Spaide: This is a case of known CNV, which can be difficult to see, as shown in Figure 3. Sometimes you need to check the flow overlay to ensure there is an anatomic correlate to what you think is CNV.

Figure 4 provides a view of the section near the inner plexus. At the bottom is a blood vessel, but if we move down into the outer plexiform layer, we can see a projection artifact (Figure 5). This

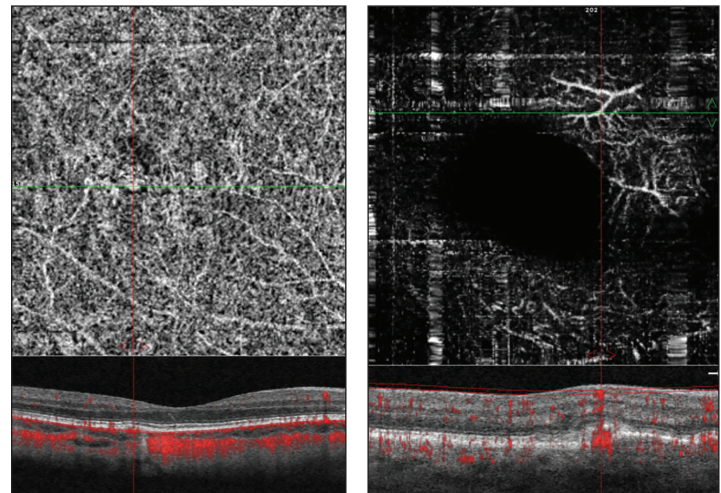


Figure 3. A patient with CNV.

Figure 4. A view of the section near the patient's inner plexus.

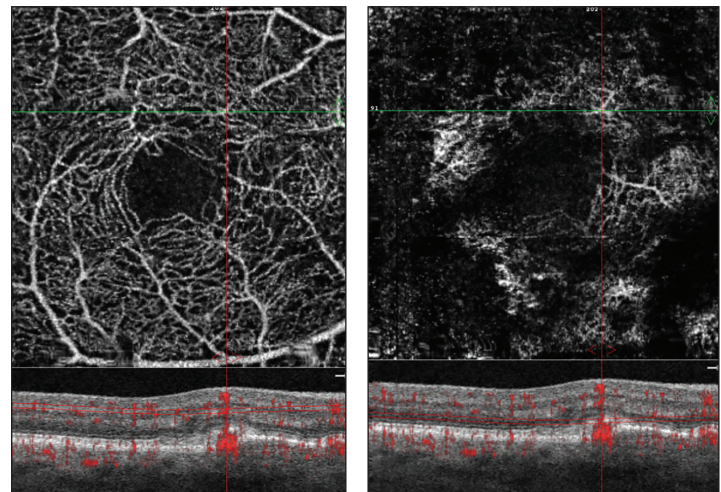


Figure 5. A projection artifact in the outer plexiform layer.

Figure 6. The artifact pertains even down into the deep retina.




Figure 7. There appears to be an admixture of the projection artifact plus real vessels in the membrane.

it is coming from.²⁷ This may be a case where the projection is sometimes better than the real thing. There appears to be an admixture of the projection artifact plus real vessels in the membrane (Figure 7) in many cases. In other cases where the center of neovascular membrane appears to be dark, it may be an artifact of shadowing or signal attenuation rather than a true absence of vessels.

Dr. Spaide: This is a case of CNV. It is almost at the level of the RPE, which is why there are so many projection artifacts.

Dr. Singh: But this is what you would expect to see with choriocapillaris.

Dr. Spaide: However, the choriocapillaris vasculature is so limited, you can barely see it.

Dr. Sadda: These might be Sattler's vessels or larger choroidal vessels.

Dr. Singh: The choroid looks thin.

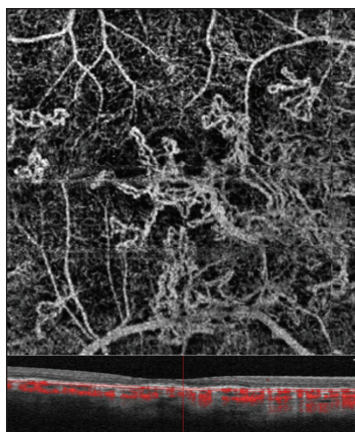


Figure 8. This is pseudoxanthoma elasticum where the choriocapillaris is nearly absent.

artifact pertains even down into the deep retina (Figure 6). Bear in mind that any reflective layers will result in a projection artifact. All you need is a source for the signal, the inner retinal blood vessel, and a projection surface.

Dr. Sadda: Sometimes the projection surface or layer is better than the layer in which the abnormality actually physically exists. In myopic CNV, for example, the choroid is very thin. Although you think you are looking at the choroid scleral interface or a reflection off the sclera, that is not where

it is coming from.²⁷ This may be a case where the projection is sometimes better than the real thing. There appears to be an admixture of the projection artifact plus real vessels in the membrane (Figure 7) in many cases. In other cases where the center of neovascular membrane appears to be dark, it may be an artifact of shadowing or signal attenuation rather than a true absence of vessels.

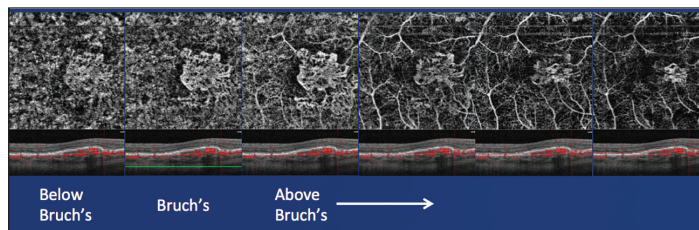


Figure 9. How do you measure lesion size?

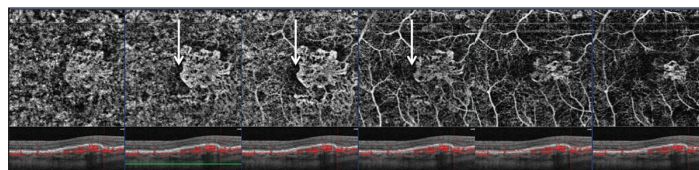


Figure 10. This patient may have a perilesional halo.

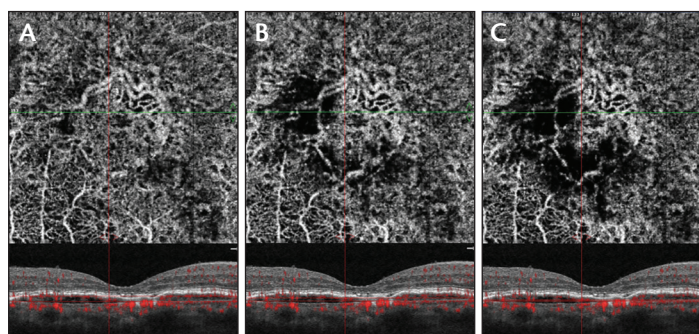


Figure 11. A perilesional halo can appear by changing the thickness of the segmentation: 50- μ m section (A), 25- μ m section (B), and 10- μ m section (C).

fits in nicely with Dr. Waheed's work. The choriocapillaris can be severely affected in disease prior to any clinically observable change in the RPE.

How do you measure lesion size (Figure 9)? This patient has three layers of CNV. In Figure 10, we have what might be perilesional halo. Some say that it is a sign of impending activity; however, I can make a perilesional halo just by changing the thickness of the segmentation (Figure 11).

Dr. Sadda: Are you saying that a perilesional halo is an artifact?

Dr. Spaide: Yes, it can be, but it can also be real. Finding a halo is highly dependent on how you look for it. Therein lies the dilemma. Perilesional halos are not necessarily signs of exudation.

Asymptomatic Patient With Evidence of CNV

Dr. Sadda: This is a 77-year-old patient who had been observed for many years for intermediate bilateral AMD. She came in for a routine follow-up. There were no symptoms. Her visual acuity was -20/30 OU. Anterior segment examination was notable for 1+NS OU. Figure 12 shows a network of vessels at the level of the PED. This is basically an asymptomatic patient with evidence of CNV on computerized tomography angiography and no fluid on examination. The question is: what do you do with this patient? Will you obtain a routine color photograph, an SD-OCT, or an OCT angiography, or even dye-based angiography?

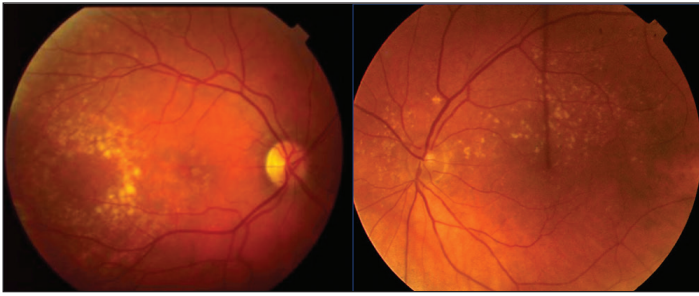


Figure 12. A patient with a network of vessels at the level of the PED.

Dr. Spaide: I would look for signs of disease first.

Dr. Sadda: What if the patient’s vision was reduced or if she had symptoms? Would you then treat?

Dr. Spaide: If the patient had symptoms, I would be more inclined to treat. If the patient had fluid, I would treat the patient. Distortion and fluid would help me make the determination.

Dr. Sadda: Unfortunately, we do not have the data to support treating patients at this point.

Dr. Spaide: We fundamentally know treating patients with CNV who show signs of disease activity is better than observation. If you embark on treatment for patients who require it, you need to continue for the rest of their lives, and you need to have good data.

Dr. Sadda: This patient obviously did not require treatment; so how would you observe her.

Dr. Singh: You might want to observe her monthly for a while.

Dr. Spaide: I agree.

Dr. Sadda: I think that is reasonable. These are some of the questions you need to ask yourself when faced with such a patient:

- Should I treat with anti-VEGF therapy?
- What if the patient had reduced vision or symptoms?
- What if the patient had no symptoms but mild retinal fluid (no hemorrhage)?
- What are the key factors that tip you to treatment?
- Would results of a FA alter your decision-making?
- How would you observe this patient?

The key takeway is that there are probably many patients with asymptomatic CNV that can be detected on OCT angiography, and that we do not have data yet on whether these patients or a subset of these patients should be treated. ■

1. Maguire MG, Martin DF, et al; Comparison of Age-related Macular Degeneration Treatments Trials Research Group. Five-year outcomes with anti-vascular endothelial growth factor treatment of neovascular age-related macular degeneration: The comparison of age-related macular degeneration treatments trials. *Ophthalmology*. 2016;123(8):1751-1761.
2. Bhisitkul RB, Desai SJ, Boyer DS, et al. Fellow eye comparisons for 7-year outcomes in ranibizumab-treated AMD subjects from ANCHOR, MARINA, and HORIZON (SEVEN-UP Study). *Ophthalmology*. 2016;123(6):1269-1277.
3. Heier JS, Brown DM, Chong V, et al. Intravitreal aflibercept (VEGF trap-eye) in wet age-related macular degeneration. *Ophthalmology*. 2012;119(12):2537-2548.
4. Schmidt-Erfurth U, Kaiser PK, Korobelnik JF, et al. Intravitreal aflibercept injection for neovascular age-related macular degeneration: Ninety-six-week results of the VIEW studies. *Ophthalmology*. 2014;121(1):193-201.
5. Marcus DM. Long-term follow-up of intravitreal injection for neovascular age-related macular degeneration in an open-label extension of the VIEW 1 study. Presented at: the Association for Research in Vision and Ophthalmology Annual Meeting; May 4-8, 2014; Orlando, FL.
6. ClinicalTrials.gov. Treat and extend therapy study using intravitreal aflibercept for patients exited from Protocol VEGT-OD 0910 (RANGE). <https://clinicaltrials.gov/ct2/show/NCT09161414>. Updated October 29, 2015. Accessed January 17, 2016.
7. Wu L, Martinez-Castellanos MA, Quiroz-Mercado H, et al. Twelve-month safety of intravitreal injections of bevacizumab (Avastin): Results of the Pan-American Collaborative Retina Study Group (PACORES). *Graefes Arch Clin Exp Ophthalmol*. 2008;246(1):81-87.
8. Peden MC, Suner IJ, Hammer ME, Grizzard WS. Long-term outcomes in eyes receiving fixed-interval dosing of anti-vascular endothelial growth factor agents for wet age-related macular degeneration. *Ophthalmology*. 2015;122(4):803-808.
9. Gillies MC, Campain A, Barthelmes D, et al. Long-term outcomes of treatment of neovascular age-related macular degeneration: Data from an observational study. *Ophthalmology*. 2015;122(9):1837-1845.
10. Rasmussen A, Bloch SB, Fuchs J, et al. A 4-year longitudinal study of 555 patients treated with ranibizumab for neovascular age-related macular degeneration. *Ophthalmology*. 2013;120(12):2630-2636.
11. Hanutsaha P. Indocyanine-green videoangiography of drusen as a possible predictive indicator of exudative maculopathy. *Ophthalmology*. 1998;105(9):1632-1636.
12. Fung AT, Kumar N, Vance SK, et al. Pilot study to evaluate the role of high-dose ranibizumab 2.0 mg in the management of neovascular age-related macular degeneration in patients with persistent/recurrent macular fluid <30 days following treatment with intravitreal anti-VEGF therapy (the LAST Study). *Eye (Lond)*. 2012;26(9):1181-1187.
13. Busbee BG, Ho AC, Brown DM, et al. Twelve-month efficacy and safety of 0.5 mg or 2.0 mg ranibizumab in patients with subfoveal neovascular age-related macular degeneration. *Ophthalmology*. 2013;120(5):1046-1056.
14. Martin DF, Maguire MG, et al; Comparison of Age-related Macular Degeneration Treatments Trials Research Group. Ranibizumab and bevacizumab for treatment of neovascular age-related macular degeneration: two-year results. *Ophthalmology*. 2012;119(7):1388-1398.
15. Wong TY, Ferreira A, Hughes R, et al. Epidemiology and disease burden of pathologic myopia and myopic choroidal neovascularization: an evidence-based systematic review. *Am J Ophthalmol*. 2014;157(1):9-25.e12.
16. Rofagha S, Bhisitkul RB, Boyer DS, et al. Seven-year outcomes in ranibizumab-treated patients in ANCHOR, MARINA, and HORIZON: A multicenter cohort study (SEVEN-UP). *Ophthalmology*. 2013;120(11):2292-2299.
17. Regillo CD, Busbee BG, Ho AC, et al. Baseline predictors of 12-month treatment response to ranibizumab in patients with wet age-related macular degeneration. *Am J Ophthalmol*. 2015;160(5):1014-1023.e1012.
18. Martin DF, Maguire MG, Ying GS, et al; CATT Research Group. Ranibizumab and bevacizumab for neovascular age-related macular degeneration. *N Engl J Med*. 2011;364(20):1897-1908.
19. Sato T, Suzuki M, Ooto S, Spaide RF. Multimodal imaging findings and multimodal vision testing in neovascular age-related macular degeneration. *Retina*. 2015;35(7):1292-1302.
20. Kumar N, Mrejen S, Fung AT, et al. Retinal pigment epithelial cell loss assessed by fundus autofluorescence imaging in neovascular age-related macular degeneration. *Ophthalmology*. 2013;120(2):334-341.
21. Photocoagulation for diabetic macular edema. Early Treatment Diabetic Retinopathy Study report number 1. Early Treatment Diabetic Retinopathy Study research group. *Arch Ophthalmol*. 1985;103(12):1796-1806.
22. Spaide RF, Fujimoto JG, Waheed NK. Image artifacts in optical coherence tomography angiography. *Retina*. 2015;35(11):2163-2180.
23. Gong J, Yu S, Gong Y, et al. The diagnostic accuracy of optical coherence tomography angiography for neovascular age-related macular degeneration: A comparison with fundus fluorescein angiography. *J Ophthalmol*. 2016;2016:7521478.
24. de Carlo TE, Bonini Filho MA, Chin AT, et al. Spectral-domain optical coherence tomography angiography of choroidal neovascularization. *Ophthalmology*. 2015;122(6):1228-1238.
25. Bonini Filho MA, de Carlo TE, Ferrara D, et al. Association of choroidal neovascularization and central serous chorioretinopathy with optical coherence tomography angiography. *JAMA Ophthalmol*. 2015;133(8):899-906.
26. Eldred GE, Katz ML. Fluorophores of the human retinal pigment epithelium: separation and spectral characterization. *Exp Eye Res*. 1988;47(1):71-86.
27. Maruko I, Spaide RF, Koizumi H, et al. Choroidal blood flow visualization in high myopia using a projection artifact method in optical coherence tomography angiography [published online ahead of print August 18, 2016]. *Retina*. doi: 10.1097/IAE.0000000000001324.

INSTRUCTIONS FOR CME CREDIT

To receive *AMA PRA Category 1 Credit*,™ you must complete the Post Test and Activity Evaluation and mail or fax to Evolve Medical Education LLC; PO Box 358, Pine Brook, NJ 07058; Fax: (610) 771-4443. To answer these questions online and receive real-time results, please visit evolvemed.com and click "Online Courses." If you are experiencing problems with the online test, please email us at support@evolvemed.com. Certificates are issued electronically, please provide your email address below.

Please type or print clearly, or we will be unable to issue your certificate.

Name _____ MD participant non-MD participant

Phone (required) _____ Email (required) _____

Address _____

City _____ State _____

AMD IN 2017: A REVIEW OF TREATMENT GUIDELINES AND THE ROLE OF EARLY APPROPRIATE THERAPY CME QUESTIONS

1 *AMA PRA Category 1 Credit*™

Expires February 2018

- The presence of _____ should call your attention to CNV activity.**
 - Foveal resistance
 - Vision loss
 - Subretinal fluid
 - Atrophy
- The biggest contributor to vision loss may be _____.**
 - Fibrotic lesions
 - Decreased choroidal circulation
 - Undertreatment
 - Geographic atrophy
- To be considered a fluent reader, a person must be able to read _____ words per minute.**
 - 50
 - 75
 - 90
 - 100
- _____ is an important factor in deciding to treat an asymptomatic patient.**
 - Evidence of new hemorrhage
 - Increased pigmentation
 - Vision loss
 - A large patch of atrophy
- _____ was identified as the promising technology, as it allows functional assays using the OCT, while one is looking for reflective changes that are not motion-related.**
 - Hyperspectral imaging
 - Optophysiology
 - Molecular probe
 - Fluorescein angiography
- _____ is considered the gold standard in monitoring patients with AMD.**
 - Autofluorescence
 - Fundus angiography
 - Indocyanine green angiography
 - Combination of FA plus structural OCT
- Making a definitive diagnosis of AMD requires the presence of _____.**
 - Many intermediate drusen or one large druse
 - A ballooned subretinal pigment
 - A thickened choroid
 - Hypertension
- Limitations of the PACORES study included _____.**
 - Monthly patient follow-ups
 - Too few injections of anti-VEGF per year
 - Too few study subjects
 - A brief follow-up period

ACTIVITY EVALUATION

Did the program meet the following educational objectives?

Agree Neutral Disagree

Understand the most recent monotherapy and combination therapy clinical study evidence using available anti-VEGF therapies for common retinal diseases, including AMD

Discuss the ocular and systemic effects of anti-VEGF therapies and how to educate patients on appropriate expectations

Develop plans to initiate treatment for conditions such as AMD using anti-VEGF agents, as well as better understand when to change therapeutic strategies

Your responses to the questions below will help us evaluate this CME activity. They will provide us with evidence that improvements were made in patient care as a result of this activity as required by the Accreditation Council for Continuing Medical Education (ACCME).

Name and email: _____

Do you feel the program was educationally sound and commercially balanced? Yes No

Comments regarding commercial bias:

Rate your knowledge/skill level prior to participating in this course: 5 = High, 1 = Low _____

Rate your knowledge/skill level after participating in this course: 5 = High, 1 = Low _____

Would you recommend this program to a colleague? Yes No

Do you feel the information presented will change your patient care? Yes No

Please identify how you will improve/change: _____

Change the management and/or treatment of patients. Please specify:

Create/revise protocols, policies, and/or procedures. Please specify:

Please identify the barriers to change.

___ Cost ___ Lack of consensus or professional guidelines ___ Lack of administrative support ___ Lack of experience

___ Lack of time to assess/counsel patients ___ Lack of opportunity (patients) ___ Reimbursement/insurance issues

___ Lack of resources (equipment) ___ Patient compliance issues ___ No barriers ___ Other

Please specify: _____

To help evaluate this CME activity, may we contact you by email in 1 to 2 months to see if you have made this change? If so, please provide your email address below.

Please list any additional topics you would like to have covered in future Evolve Medical Education LLC CME activities or other suggestions or comments.
